02/24

BJ

BANTAO Journal

Official Publication of the BANTAO Association

Incorporating Proceedings of the BANTAO Association

Editor-in-Chief

Goce Spasovski Skopje

Editores Emeriti

Dimitr Nenov Varna
Momir Polenakovic† Skopje
Ljubica Djukanovic Belgrade
Charalambos Stathakis† Athens
Ali Basci Izmir

Associate Editors

Mustafa Arici Ankara
Nada Dimkovic Belgrade
Evangelos Papachristou Patra
Nikolina Basic-Jukic Zagreb

Deputy Editors

Veselin Nenov Varna
Adrian Covic Iasi

Editorial Board

Adalbert Schiller Timisoara
Aikaterini Papagianni Thessaloniki
Alma Idrizi Tirana
Amira Peco Antic Belgrade
Aydin Turkmen Istanbul
Biljana Stojmirovic Belgrade
Damir Rebic Sarajevo
Daniela Monova Sofia
Dimitris Goumenos Patra
Emil Paskalev Sofia
Evgueniy Vazelov Sofija
Fehmi Akcicek Izmir
Fevzi Ersoy Antalya
Flaviu Bob Timisoara
Gjulsen Selim Skopje
Gordana Peruncic-Pekovic Belgrade
Gultekin Suleymanlar Antalya
Halima Resic Sarajevo
Igor Mitic Novi Sad
Irena Rambabova Busletikj Skopje
Jadranka Buturovic-Ponikvar Ljubljana
John Boletis Athens
Kamil Serdengecti Istanbul
Kenan Ates Ankara
Liliana Garneata Bucharest
Mahmut Ilker Yilmaz Ankara
Merita Rroji Tirana
Milan Radovic Belgrade
Milorad Grujicic Banja Luka
Myftar Barbullushi Tirana
Nikolina Smokovska Skopje
Petar Kes Zagreb
Rade Naumovic Belgrade
Rafael Ponikvar Ljubljana
Rumeyza Kazancioglu Istanbul
Sanja Simic-Ogrizovic Belgrade
Sanjin Racki Rijeka
Serhan Tuglular Istanbul
Sevgi Mir Izmir
Tekin Akpolat Samsun
Vassilios Liaikopoulos Thessaloniki
Velibor Tasic Skopje
Vidojko Djordjevic Nis
Visnja Lezaic Belgrade

International Advisory Board

Andrzej Wiecek Poland
Claudio Ponticelli Italy
Carmine Zoccali Italy
David Goldsmith UK
Francesco Locatelli Italy
Horst Klinkmann Germany
Ivan Rychlik Prague
John Feehally UK
Jorg Vienken Germany
Jorge Cannata Spain
Jurgen Floege Germany
Marc De Broe Belgium
Markus Ketteler Germany
Mohamed Daha Netherlands
Norbert Lameire Belgium
Raymond Vanholder Belgium
Rosanna Coppo Italy
Ziad Massy France

Published by: Balkan Cities Association of Nephrology, Dialysis, Transplantation and Artificial Organs

Printing: BANTAO, 2025

BANTAO Journal 2023; 22(2): 25-31

BJ
BANTAO Journal

Original article

Anti-Cytomegalovirus Hyperimmune Immunoglobulins As Adjunctive Therapy During Acute COVID-19 In Kidney Transplant Recipients: A Single-Center Retrospective Cohort Study

Nikolina Basic-Jukic[1,2], Lea Katalinic[1], Ivana Juric[1], Vesna Furic-Cunko[1], Marina Kljajic[2], Armin Atic[1] and Zoran Sabljic[1]

[1]Department of Nephrology, Arterial Hypertension, Dialysis and Transplantation, Clinical Hospital Centre Zagreb, [2]School of Medicine, University of Zagreb, Zagreb, Croatia

Abstract

Introduction. Anti-CMV immunoglobulin (CMV-HIG) contains antibodies against various infective pathogens and not only against the cytomegalovirus (CMV), thus possibly mimicking the convalescent plasma.
Methods. A retrospective analysis concerning the practice of CMV-HIG off-label use during acute COVID-19 in kidney transplant recipients (KTR).
Results. From March 2020 to August 2022, 403 KTR (59.8% male) who developed COVID-19 were eligible for investigation. Hundred and fifty one (44,4%) patients required hospitalization, and eighteen (5,6%) mechanical ventilation. Thirty-four (8.4%) patients received CMVHIG. Two patients had CMV reactivation and received CMVHIG 2 ml/kg in five doses. Others had hypogammaglobulinemia which was an additional off-label indication for using CMVHIG during acute COVID-19. Twenty two patients (6.5%) died, 4 of them from the CMVHIG group.
Conclusion. A correction of hypogammaglobulinemia, potential remodeling of the immunological response, and CMV reactivation during acute infection, may justify the use of CMVHIG during acute COVID-19.

Keywords: COVID-19, SARS-CoV-2, CMV, hyperimmune anti-CMV globulin

Introduction

The pandemic of the coronavirus disease 2019 (COVID-19) has resulted in more than 690 million infections and almost 7 million deaths by July 2023 [1]. Advanced age, obesity, hypertension, diabetes, immunosuppression, and other chronic diseases have all been associated with increased severity of COVID-19 [2-4]. However, almost 50% of severe cases occur without obvious pre-existing conditions [4]. Cytomegalovirus (CMV) is a widely prevalent herpes virus. CMV-induced immune system remodeling was suggested in the pathogenesis of SARS-CoV-2 infection, and may be associated with more severe COVID-19 forms [5,6].
Treatment of acute COVID-19 remains challenging, while even vaccination failed to protect immunocompromised patients due to frequent breakthrough infections [7]. COVID-19 convalescent plasma (CP) contains neutralizing SARS-CoV-2 antibodies obtained from patients who recovered from acute COVID-19 but has been used with inconsistent results [8,9]. However, it had an important role in the early era of COVID-19 treatment when neither effective vaccines nor monoclonal antibodies were available on the market. Although the role of CP remains controversial, it may remain an important tool for the treatment of immunocompromised patients [10]. Intravenous immunoglobulins (IVIG) are widely used as additional treatment for patients with severe COVID-19 due to their immunomodulatory actions which can be potentially useful [11-14]. Hyperimmune anti-CMV immunoglobulin (CMV-HIG) has been approved as an adjuvant treatment for patients with CMV infection [15]. The product contains antibodies against various infective pathogens and not only against the CMV [16], thus possibly mimicking the convalescent plasma. At the beginning of the COVID-19 pandemic, with no available treatment or vaccine, we were the first to hypothesize that CMV-HIG might provide passive protection against SARS-CoV-2 [17].
Herein, we report our experience in off-label treatment of kidney transplant recipients with CMVIG in the context of SARS-CoV-2 infection.

Material and methods

This retrospective observational study comprised kidney transplant recipients with acute SARS-CoV-2 infection who received off-label CMV-HIG during

Correspondence to: Nikolina Basic-Jukic, Department of Nephrology, Arterial Hypertension, Dialysis and Transplantation, Clinical Hospital Centre Zagreb, Kispaticeva 12, 10000 Zagreb, Croatia; E-mail: nina_basic@net.hr

acute SARS-CoV-2 infection. Treatment was individually chosen according to the attending transplant nephrologist. It was based on patients' history, severity of acute COVID-19 and laboratory findings (hypogammaglobulinemia, positive CMV DNA). The study was approved by the Ethics Committee with the informed consent from the patients.

Primary outcomes of the study were indications for the use of CMV-HIG (prevention or therapy of CMV infection), CMV-HIG protocol and dosages. Secondary outcomes included outcome of treatment, percentage of patients who reactivate CMV, adverse events, rehospitalizations after acute COVID-19, and follow-up results from the start of treatment until 6 months after the end of treatment with CMVHIG.

To assess clinical complications, patients were interviewed by a standardized survey by trained transplant nephrologists to recount symptoms during the acute illness and whether they persisted or some new occurred to assess clinical complications. Patients also underwent a detailed physical examination. Additional diagnostic methods were used individually (laboratory, radiologic). Data on immunosuppressive regimen and acute COVID-19 characteristics were recorded. Venous blood samples were collected for complete blood count, biochemistry, coagulation examinations (prothrombin time (PT), activated partial thromboplastin time (APTT) and fibrinogen), D-dimers, C3, C4, total complement, platelet aggregation with ADP (adenosine 5′-diphosphate), serum electrophoresis, donor-specific antibodies, and virology (molecular diagnostic detection for cytomegalovirus (CMV), Epstein-Barr virus (EBV) and BK virus (BKV)). Donor specific antibodies were determined by Luminex bead-based technology (One lambda). Results were compared with historical values. We had no data regarding the SARS-CoV-2 serology.

Patients have been followed-up continuously, with reassessment at six months after acute SARS-CoV-2 infection.

Categorical data were presented by absolute and relative frequencies. The normality of the distribution of continuous variables was tested by the Shapiro-Wilk test. Continuous data were described by the median and the limits of the interquartile range (IQR). The Mann-Whitney U test was used to compare the median between two groups, while Fisher's exact test was used to analyze the differences between proportions. Logistic regression analysis was used to analyze the independent factors associated with the development of clinical complications or laboratory abnormalities. A stepwise multivariable logistic regression was used to assess the association between potential risk factors and development of laboratory or clinical complications, adjusting for known confounders. Variables assessed included demographic characteristics (i.e., age, gender, primary kidney disease), clinical characteristics (i.e., different comorbidities), acute COVID-19 characteristics (i.e., presentation, need for hospitalization). Parameters with statistical significance in the univariate analysis were incorporated into the multivariate logistic regression model for in-depth analysis. The level of significance was set at an Alpha of 0.05. Considering the relatively small sample size and the possibility of overfitting in the multivariate logistic regression model, we adopted a forward stepwise method (probability for stepwise: entry $P<0.05$, removal $P>0.1$) for logistic regression analysis to reduce the number of independent variables entering the model. There was no substitution of the missing data. The statistical analysis was performed using MedCalc® Statistical Software version 19.6 (MedCalc Software Ltd, Ostend, Belgium; https://www.medcalc.org; 2020) and the IBM SPSS Stat. 23 (IBM Corp. Released 2015. IBM SPSS Statistics for Windows, Version 23.0. Armonk, NY: IBM Corp.).

Results

From March 2020 to August 2022, 403 patients (59.8 % male) who received renal allograft at our institution developed COVID-19 and were eligible for investigation. The most common primary kidney diseases were glomerulonephritis (28%) and autosomal dominant polycystic kidney disease (15.3%).

Patients' characteristics are presented in Table 1. Hospitalization during acute SARS-CoV-2 infection was necessary for 151(44,4%) patients. Eighteen (5,6%) patients required mechanical ventilation. Thirty-four (8.4%) patients received CMVHIG during acute COVID-19.

Table 1. Patients' characteristics. TX, transplantation; BMI, body mass index; No, number, CKD-EPI eGFR, Chronic Kidney Disease Epidemiology Collaboration estimated glomerular filtration rate; IQR, interquartile range

	Median (IQR)			P*
	CMVHIG	Other	Total	
Age (years)	52.5(45-66.5)	57(46-64.75)	57(46-65)	0.57
TX vintage (months)	85.5(59-138.75)	96.5(53-138)	95.5(53-137.75)	0.88
BMI (kg/m^2)	25.14(23.4-28.48)	26.6(23.98-29.37)	26.5(23.92-29.32)	0.17
No of AHT drugs	3(1-4)	2(1-3)	2(1-4)	0.04
Steroid dose	5(5-7,5)	5(5-5)	5(5-5)	0.11
CKD-EPI eGFR	42.5(32-53.5)	49(35-63)	48(35-62)	0.13
Proteinuria	0.32(0.17-0.91)	0.23(0.12-0.49)	0.23(0.13-0.51)	0.03

*Mann Whitney U test

Eleven patients (33%) from the CMVHIG group and forty-six (20%) from the non-CMVHIG group received at least one dose of vaccine before developing acute COVID-19.

Patients who received CMVHIG more frequently had diabetes (38,3% vs.22,6%, p=0,04), a history of CMV infection after the transplantation (24,2% vs. 10,1%, p=0,01), needed more antihypertensive drugs and more frequently had a history of acute rejection (26,5 vs. 13,1 %, p=0,03).

During acute COVID-19, patients treated with CMVHIG more frequently had pneumonia that required hospitalization and mechanical ventilation (Table 2).

Table 2. Clinical presentation during acute COVID-19 in patients treated with CMVHIG and patients wo did not receive CMVHIG. Other symptoms included chest pain, abdominal pain, and loss of smell and taste

Acute COVID	Number (%) patients			P*
	CMVHIG	Other	Total	
Febrility	29(85.3)	252(80.3)	281(80.7)	0.48
Diarrhoea	9(26.5)	46(14.7)	55(15.9)	0.08
Respiratory	27(79.4)	226(72.7)	253(73.3)	0.40
No symptoms	1(3)	24(7.8)	25(7.3)	0.49†
Pneumonia	30(90.9)	135(45)	165(49.5)	<0.001
Other symptoms	15(44.1)	61(16.5)	76(18.9)	<0.001
Hospitalization	31(93.9)	120(39.1)	151(44.4)	<0.001
Mechanical ventilation	5(17.9)	13(4.4)	18(5.6)	0.01†

*χ^2 test, †Fisher exact test

Treatment during acute SARS-CoV-2 infection included immunosuppression modification in 261 patients (64.7%) (Table 3), remdesivir (61 patients (52,1%)), hydroxychloroquine (12 patients (2.9%), prophylactic use of low-molecular-weight heparin, glucocorticoids and antibiotics. Additionally, besides the patients who were treated with CMVHIG (34 patients, 8.4%), 17 patients (5.5%) received intravenous immunoglobulins, and four (1%) received convalescent plasma. Four patients (1%) were treated with tocilizumab. Other patients did not receive specific treatment because they either had a mild disease or did not inform us timely about the infection.

Table 3. Immunosuppressive therapy modification during acute COVID-19

	Number (%) of patients			P*
	CMVHIG	Other	Total	
MMF/Aza cessation	26(78.8)	122(41.8)	148(45.5)	<0.001
Decreased MMF/Aza	7(21.9)	106(36.3)	113(34.9)	0.12
Tac/CyA cessation	4(12.9)	1(0.3)	5(1.6)	<0.001
Decrease Tac/Cya	0	26(9)	26(8.9)	>0.99

*Fisher exact test

Two patients had positive CMV DNA during acute COVID-19. Besides the ganciclovir, they both received CMVHIG 2 ml/kg in five doses. Hypogammaglobulinemia was an additional off-label indication for using CMVHIG during acute COVID-19. Hyperimmune anti-CMV globulin was applied in the dose of 1 ml/kg in 1 to 3 doses depending on the condition of patients, but also on the length of hospitalization.

Twenty-two patients (6.5%) died during acute COVID-19 (18 from multiorgan failure, three from myocardial infarction, and one from resistant CMV infection). Four of them were from the CMVHIG group.

Patients who survived acute COVID-19 underwent post-COVID-19 follow-up at the ambulatory visit 6-8 weeks after the infection. CMV reactivation was recorded in 21.7% of patients after recovery from acute COVID-

Table 4. Post-COVID complications in patients treated with CMVHIG and patients who did not receive CMVHIG during acute COVID-19

	Number (%) of patients			P*
	CMVHIG	Other	Total	
Kidney biopsy	4(16.7)	12(5.2)	16(6.3)	0.05
Neuropathy	0	10(4.3)	10(3.9)	0.61
CMV	7(30.4)	45(20.7)	52(21.7)	0.29
BKV	6(27.3)	54(25)	60(25.2)	0.80
EBV	12(54.5)	77(35.8)	89(37.6)	0.11
Hypogammaglobulinemia	10(45.5)	62(30.7)	72(32.1)	0.31

*Fisher exact test, Abbreviations, CMV, cytomegalovirus, EBV, Epstein Barr virus, BKV, BK virus

Table 5. Post-COVID-19 laboratory analysis

	Median (IQR)			P*
	CMVHIG	Other	Total	
Proteinuria	0.25(0.13-1.1)	0.26(0.14-0.59)	0.26(0.13-0.59)	0.70
CKD-EPI eGFR	44(28-58)	50(35.25-69)	49(35-69)	0.15
D-dimers	1.31(0.55-1.96)	0.56(0.34-1.06)	0.57(0.35-1.26)	0.01
Prothrombin time	1.17(1.08-1.27)	1.13(1.02-1.23)	1.13(1.04-1.24)	0.31
APTT	21.75(20.08-23.7)	22.2(20.8-23.4)	22.2(20.8-23.4)	0.52
Fibrinogen	4.6(3.3-6.45)	3.4(2.93-4.4)	3.5(3-4.55)	0.01
Plattelet aggregation	71(62-78.5)	78(72-85)	78(72-84)	0.004
C3	1.21(0.99-1.46)	1.23(1.06-1.47)	1.22(1.06-1.46)	0.63
C4	0.30(0.23-0.36)	0.26(0.21-0.33)	0.26(0.21-0.33)	0.19
CH50	105(94-122)	105.5(94-113)	105(94-114)	0.51

*Mann Whitney U test; Abbreviations: CKD-EPI eGFR, Chronic Kidney Disease Epidemiology Collaboration estimated glomerular filtration rate; APTT, activated partial thromboplastin time

19, with no statistically significant difference between patients who received CMVHIG during acute COVID-19 (30.4%) and patients who did not receive CMVHIG (20.7%). There were no significant differences in post-COVID complications between groups (Table 4).

Laboratory analysis performed after acute COVID-19 revealed increased D-dimers, fibrinogen, and platelet aggregation in patients treated with CMVHIG compared to patients who did not receive CMVHIG (Table 5).

In bivariate logistic regression analysis, diabetes mellitus, the severity of acute COVID-19, and kidney allograft dysfunction during acute infection were identified as significant predictors for CMV reactivation after recovery from SARS-CoV-2 infection (Table 6), however, the number of cases needed to be bigger for multivariate analysis.

Table 6. Bivariate logistic regression analysis for prediction of CMV reactivation after recovery from acute COVID-19

Bivariate analysis	ß	Wald	OR (95% CI)	P
Therapy (CMVHIG vs. other)	0.51	1.13	1.67(0.64-4.31)	0.29
Diabetes	0.68	3.87	1.98(1.01-3.9)	0.04
Febrility	1.06	4.48	2.89(1.08-7.72)	0.03
Respiratory symptoms	1.35	8.49	3.8(1.56-9.5)	0.004
Pneumonia	1.15	11.5	3.15(1.62-6.09)	<0.001
Other complications during COVID-19	0.80	4.74	2.22(1.08-4.56)	0.03
Allograft dysfunction	0.23	3.91	10.2(1.02-101.5)	0.04
MMF/Aza cessation	0.74	5.25	2.09(1.11-3.94)	0.02
CMVHIG	0.53	1.18	1.69(0.65-4.40)	0.28
IvIg	1.62	5.47	5.06(1.3-19.7)	0.02

ß-regression coeficient; Abbreviations: MMF, mycophenolate mofetil; Aza, azathioprin; CMVHIG, hyperimmune antiCMV globulin; IvIG, intravenous immunoglobulin

Within six months after acute COVID-19, 40% of patients from the CMVHIG group required hospitalization, compared to 17.3% of patients not treated with CMVHIG (p=0.01). The most common indications in both groups were pneumonia and urinary tract infections.

COVID-19 reinfection was recorded in one patient from the CMVHIG and three patients from the group not treated with CMVHIG.

Discussion

In our retrospective analysis concerning the practice of CMV-HIG off-label use during acute COVID-19, we assessed two main indications: the application of CMV-HIG as adjunctive treatment of acute COVID-19 and CMVHIG as adjunctive treatment of CMV reactivation to the antivirals during the SARS-CoV-2 infection.

Out of 34 patients treated with CMVHIG, two had concomitant SARS-CoV-2 and CMV infection, while others received CMVHIG as adjunctive therapy for COVID-19. Administration of CMVHIG was well tolerated without any side effects. Compared to the rest of our cohort, patients treated with CMVHIG had more severe acute COVID-19, as indicated by the need for mechanical ventilation.

Cytomegalovirus is one of the most significant non-genetic determinants of the immune system with its pronounced immunomodulatory effects. It has the strong potential to shape the course of SARS-CoV-2 infection, either because of CMV reactivation or due to the reshaping of immune response to SARS-CoV-2. However, it remains unclear whether CMV reactivation is a direct consequence of SARS-CoV-2 infection, or results from COVID-19 immunomodulatory therapies

[18], but was found to be associated with an increased risk of COVID-19-related hospitalizations [19]. Osawa *et al*., reported that in the population of patients hospitalized in intensive care units, steroid administration, prolonged mechanical ventilation, and sepsis have all been recognized as risk factors for CMV reactivation [20].

Prevention and treatment of acute COVID-19 are still not optimal. Vaccination of immunocompromised patients results with frequent breakthrough infections [7], and antivirals are of limited efficacy. Convalescent plasma has been used for treatment of SARS-CoV-2 infection from the beginning of the pandemic with controversial results [21-24]. Convalescent plasma seems to exert its therapeutic potential through direct viral neutralization, antibody-dependent cellular cytotoxicity, complement system activation, and phagocytosis. A cardinal factor in its efficacy is the high level of antibodies administered [25] what was not uniqe and not evaluated in majority of published studies. Dulipsingh *et al*., have shown that subjects with a single infection with SARS-CoV-2 did not have the same levels of neutralizing antibodies that we observed in subjects either in the convalescent or the naive vaccinated groups. Neutralizing antibodies were significantly higher in vaccinated patients than in the convalescent unvaccinated group [26]. As the pandemic evolved, antibody treatment transitioned from convalescent plasma (CP) to monoclonal antibody preparations [27,28]. However, convalescent plasma should still be considered for immunosuppressed COVID-19 patients.

The benefit of IVIG therapy for acute COVID-19 is also controversial [29-31]. As well as with CP, the insufficient effects of IVIG therapy may be the results of dosage, administration timing, and disease severity at the time of administration [32]. Unfortunately, IVIG was usually used for severe or critically ill patients due to the high price and possible side effects. Also, a high number of patients with severe and critical COVID-19 resulted in frequent shortages of IVIG during the pandemic. We used CMVHIG for treatment of CMV infection or for correction of hypogammaglobulinemia in hospitalized patients with moderate to severe acute COVID-19. SARS-CoV-2 infection is often associated with secondary hypogammaglobulinemia, which correlates with the risk of infection and is often treated with immune globulins to support humoral immune responses [33].

In our cohort, patients treated with CMVHIG all had moderate or severe acute COVID-19, and four patients died (11.7%). Reported mortality rates from the literature approaches up to 28% [34-36], suggesting the possible efficacy of CMVHIG as adjunctive therapy for hypogammaglobulinemic immunocompromised kidney transplant recipients and patients with CMV reactivation for treatment of CMV recativation during acute COVID-19.

Data on the use of CMV antivirals in COVID-19 patients is scarce. Interestingly, Schoninger *et al*., failed to find any clear clinical benefit to treating CMV reactivation in the COVID-19 patients in intensive care unit [37]. The ganciclovir-treated subgroup did not display an increased morality rate in the Italian study [38]. Our patients responded well to the tretament with antivirals and CMVHIG.

While data on tretament of CMV reactivations during acute COVID-19 is limited, even less is known on CMV reactivations post-COVID. In our study, fifty-two patients (12.9%) reactivated CMV infection after recovery from acute SARS-CoV-2 infection. In bivariate logistic regression analysis, diabetes mellitus, the severity of acute COVID-19, and kidney allograft dysfunction during acute infection were identified as significant predictors for CMV reactivation. There was no correlation between the treatment with CMVHIG during acute COVID-19 and CMV reactivation in the post COVID follow up.

Rehospitalizations were frequent. In our previous, multicentre study, the most common indications for hospitalization after acute COVID-19 were pneumonia (24.5%) and renal allograft dysfunction (22.4%), followed by sepsis (14.3%) and thrombotic events (10.2%). The strongest predictor for hospitalization after recovering from SARS-CoV-2 infection in this study was the hospitalization for acute COVID-19, while better allograft function decreased the probability of hospitalization [39,40].

During the post-COVID-19 follow up, patients from the CMVHIG group had significantly higher D-dimers, fibrinogen and platelet aggregation. These findings may indicate pro-inflammatory and hypercoagulable state, increasing the likelihood for induction of thromboembolism or stroke [41]. However, only one patient from the CMVHIG group had developed thromboembolic complication (embolization of the ulnary artery). Reported incidence of IVIG-induced thrombotic complications ranges from 3 to 13% [42]. Risk factors for IVIG-induced thrombosis include male gender, older age, renal insufficiency, diabetes, dyslipidemia, hypertension; immobility; coronary heart disease, history of vascular diseases, family history of thromboembolic diseases, atrial fibrillation, high-dose and high-speed IVIG infusions [43]. In our previous study, the most common laboratory abnormalities after recovery from acute COVID-19 were shortened activated partial thromboplastin time (50%), elevated D-dimers (36.5%), elevated fibrinogen (30.16%), and hypogammaglobulinemia (24%) [39].

Limitations of this study are the retrospective single-centre design, lack of randomization, and the heterogeneity of the available data. The number of patients who received CMVHIG was too small for multivariate analysis. Also, we had no detailed laboratory data during acute COVID-19 for all patients. Additionally, the

use of CMVHIG was limited by the length of hospitalization, which was often determined by the pressure of the huge number of infected patients requiring hospital treatment for SARS-CoV-2 infection. However, this is the first study on the use of CMVHIG during acute COVID-19. It indicates a potential benefit of CMVHIG during acute COVID-19 in immunocompromized, hypogammaglobulinemic kidney transplant recipients. Additionaly, based on our experience, it seems that CMVHIG may provide a certain level of antibodies against some other pathogens in the future.

Conclusion

In conclusion, a correction of hypogammaglobulinemia, potential remodeling of the immunological response, and CMV reactivation during acute infection, which adversely affect outcomes in infected individuals, may justify the use of CMVHIG during acute COVID-19.

Its role in protection from SARS-CoV-2 reinfection should be investigated. Given the limited therapeutic options and COVID-19 mortality rate, CMVHIG is worth considering. However, prospective randomized trials on the use of CMV-HIG under regimens for dosage, mode, and the time of administration are needed to obtain better efficacy and safety data.

Conflict of interest statement. None declared.

References:

1. https://covid19.who.int.
2. Wu JT, Leung K, Bushman M, *et al*. Estimating clinical severity of COVID-19 from the transmission dynamics in Wuhan, China. *Nat Med* 2020; 26(4): 506-510.
3. Zhou F, Yu T, Du R, *et al*. Clinical course and risk factors for mortality of adult inpatients with COVID-19 in Wuhan, China: a retrospective cohort study. *Lancet* 2020; 395 (10229): 1054-1062.
4. Mallow PJ, Belk KW, Topmiller M, Hooker EA. Outcomes of Hospitalized COVID-19 Patients by Risk Factors: Results from a United States Hospital Claims Database. *J Health Econ Outcomes Res* 2020; 7(2): 165-175.
5. Schinas G, Moustaka V, Polyzou E, *et al*. Targeting CMV Reactivation to Optimize Care for Critically Ill COVID-19 Patients: A Review on the Therapeutic Potential of Antiviral Treatment. *Viruses* 2023; 15(5): 1165.
6. Soderberg-Naucler C. Does reactivation of cytomegalovirus contribute to severe COVID-19 disease? *Immun Ageing* 2021; 18: 12.
7. Qin CX, Moore LW, Anjan S, *et al*. Risk of Breakthrough SARS-CoV-2 Infections in Adult Transplant Recipients. *Transplantation* 2021; 105(11): e265-e266.
8. Janiaud P, Axfors C, Schmitt AM, *et al.* Association of Convalescent Plasma Treatment With Clinical Outcomes in Patients With COVID-19: A Systematic Review and Meta-analysis. *JAMA* 2021; 325: 1185-1195.
9. Vegivinti CTR, Pederson JM, Saravu K, *et al*. Efficacy of convalescent plasma therapy for COVID-19: A systematic review and meta-analysis. *J Clin Apher* 2021; 36: 470-482.
10. Bloch EM, Focosi D, Shoham S, *et al*. Guidance on the Use of Convalescent Plasma to Treat Immunocompromised Patients With Coronavirus Disease 2019. *Clin Infect Dis* 2023; 76(11): 2018-2024.
11. Kohler H, Kaveri S. How IvIg Can Mitigate Covid-19 Disease: A Symmetrical Immune Network Model. *Monoclon Antib Immunodiagn Immunother* 2021; 40(1): 17-20.
12. Nagelkerke SQ, Kuijpers TW. Immunomodulation by IVIg and the Role of Fc-Gamma Receptors: Classic Mechanisms of Action after all? *Front Immunol* 2015; 5: 674.
13. Gelfand EW. Intravenous immune globulin in autoimmune and inflammatory diseases. *N Engl J Med* 2012; 367: 2015-2025.
14. Maddur MS, Vani J, Hegde P, *et al*. Inhibition of differentiation, amplification, and function of human TH17 cells by intravenous immunoglobulin. *J Allergy Clin Immunol* 2011; 127(3): 823-830.
15. Razonable RR, Humar A. Cytomegalovirus in solid organ transplant recipients-Guidelines of the American Society of Transplantation Infectious Diseases Community of Practice. *Clin Transplant* 2019; 33(9): e13512.
16. https://www.biotest.com/de/de/produkte/klinische_immunologie/cytotect_cp/produktprofil. cfm.
17. Basic-Jukic N. Can hyperimmune anti-CMV globulin substitute for convalescent plasma for treatment of COVID-19? *Med Hypotheses* 2020; 144: 109903.
18. Naendrup JH, Garcia Borrega J, Eichenauer DA, *et al*. Reactivation of EBV and CMV in Severe COVID-19-Epiphenomena or Trigger of Hyperinflammation in Need of Treatment? A Large Case Series of Critically ill Patients. *J Intensive Care Med* 2021; 37: 1152-1158.
19. Alanio C, Verma A, Mathew D, *et al*. Cytomegalovirus Latent Infection is Associated with an Increased Risk of COVID-19-Related Hospitalization. *J Infect Dis* 2022; 226(3): 463-473.
20. Osawa R, Singh N. Cytomegalovirus infection in critically ill patients: A systematic review. *Crit Care* 2009; 13: R68.
21. Balcells ME, Rojas L, Le Corre N, *et al*. Early versus deferred anti-SARS-CoV-2 convalescent plasma in patients admitted for COVID-19: a randomized phase II clinical trial. *PLoS Med* 2021; 18: e1003415.
22. Libster R, Perez Marc G, Wappner D, *et al.* Early high-titer plasma therapy to prevent severe Covid-19 in older adults. *N Engl J Med* 2021; 384: 610-618.
23. Pouladzadeh M, Safdarian M, Eshghi P, *et al*. A randomized clinical trial evaluating the immunomodulatory effect of convalescent plasma on COVID-19-related cytokine storm. *Intern Emerg Med* 2021; 16(8): 2181-2191.
24. RECOVERY Collaborative Group. Convalescent plasma in patients admitted to hospital with COVID-19 (recovery): a randomised controlled, open-label, platform trial. *Lancet* 2021; 397: 2049-2059.
25. Focosi D, Franchini M, Pirofski LA, *et al*. COVID-19 convalescent plasma and clinical trials: understanding conflicting outcomes. *Clin Microbiol Rev* 2022; 35: e0020021.
26. Dulipsingh L, Schaefer EJ, Wakefield D, *et al*. Comparing SARS-CoV-2 neutralizing antibody levels in convalescent unvaccinated, convalescent vaccinated, and naive vaccinated subjects. *Heliyon* 2023; 9(6): e17410.
27. Montgomery H, Hobbs FDR, Padilla F, *et al.* Efficacy and safety of intramuscular administration of tixagevimab-cilgavimab for early outpatient treatment of COVID-19 (TACKLE): a phase 3, randomised, double-blind, placebo-controlled trial. *Lancet Respir Med* 2022; 10: 985-996.
28. O'Brien MP, Forleo-Neto E, Sarkar N, *et al*. Effect of subcutaneous casirivimab and imdevimab antibody combination versus placebo on development of symptomatic

COVID-19 in early asymptomatic SARS-CoV-2 infection: a randomized clinical trial. *JAMA* 2022; 327: 432-441.
29. Marcec R, Dodig VM, Radanovic I, Likic R. Intravenous immunoglobulin (IVIg) therapy in hospitalised adult COVID-19 patients: A systematic review and meta-analysis. *Rev Med Virol* 2022; 32(6): e2397.
30. Kwapisz D, Bogusławska J. Intravenous immunoglobulins (IVIG) in severe/critical COVID-19 adult patients. *Biomed Pharmacother* 2023; 163: 114851.
31. Raman RS, Bhagwan Barge V, Anil Kumar D, *et al*. A phase II safety and efficacy study on prognosis of moderate pneumonia in coronavirus disease 2019 patients with regular intravenous immunoglobulin therapy. *J Infect Dis* 2021; 223: 1538-1543.
32. Saghazadeh A, Rezaei N. Towards treatment planning of COVID-19: Rationale and hypothesis for the use of multiple immunosuppressive agents: Anti-antibodies, immunoglobulins, and corticosteroids. *Int Immunopharmacol* 2020; 84: 106560.
33. Scarpa R, Dell'Edera A, Felice C, *et al*. Impact of Hypogammaglobulinemia on the Course of COVID-19 in a Non-Intensive Care Setting: A Single-Center Retrospective Cohort Study. *Front Immunol* 2022; 13: 842643.
34. Hilbrands LB, Duivenvoorden R, Vart P, *et al*. COVID-19-related mortality in kidney transplant and dialysis patients: results of the ERACODA collaboration. *Nephrol Dial Transplant* 2020; 35: 1973-1983.
35. Caillard S, Chavarot N, Francois H, *et al*. French SOT COVID Registry. Is COVID-19 infection more severe in kidney transplant recipients? *Am J Transplant* 2021; 21: 1295-1303.
36. Cravedi P, Mothi SS, Yorg A, *et al*. COVID-19 and kidney transplantation: Results from the TANGO International Transplant Consortium. *Am J Transplant* 2020; 20: 3140-3148.
37. Schoninger S, Dubrovskaya Y, Marsh K, *et al*. Outcomes of Cytomegalovirus Viremia Treatment in Critically Ill Patients With COVID-19 Infection. *Open Forum Infect Dis* 2022; 9: ofac286.
38. Gatto I, Biagioni E, Coloretti I, *et al*. Cytomegalovirus blood reactivation in COVID-19 critically ill patients: Risk factors and impact on mortality. *Intensive Care Med* 2022; 48: 706-713.
39. Basic-Jukic N, Juric I, Furic-Cunko V, *et al*. Follow-up of renal transplant recipients after acute COVID-19-A prospective cohort single-center study. *Immun Inflamm Dis* 2021; 9(4): 1563-1572.
40. Basic-Jukic N, Racki S, Tolj I, *et al*. Hospitalization and death after recovery from acute COVID-19 among renal transplant recipients. *Clin Transplant* 2022; 36(4): e14572.
41. Lopes LA, Agrawal DK. Thromboembolism in the Complications of Long COVID-19. *Cardiol Cardiovasc Med* 2023; 7(2): 123-128.
42. Rajabally YA, Kearney DA. Thromboembolic complications of intravenous immunoglobulin therapy in patients with neuropathy: a two-year study. *J Neurol Sci* 2011; 308: 124-127.
43. Spath PJ, Granata G, La Marra F, *et al*. On the dark side of therapies with immunoglobulin concentrates: the adverse events. *Front Immunol* 2015; 6: 11.

BANTAO Journal 2023; 22(2): 32-36

BJ
BANTAO Journal

Original article

Diagnostic Values of PSA, Prostatic Volume and Neutrophil/ Lymphocyte Ratio in Predicting Prostatic Cancer

Vesna Ristovska[1], Pavlina Dzekova-Vidimliski[1], Vlatko Karanfilovski[1], Lada Trajcevska[1], Galina Severova[1], Igor Nikolov[1] and Gordana Petrusevska[2]

[1]University Hospital of Nephrology, [2]Institute of Pathology, Medical Faculty, University Ss Cyril and Methodius, Skopje, Republic of North Macedonia

Abstract

Introduction. prostate cancer is not only urological, but frequently also a problem in nephrology.
Methods. In order to find the diagnostic values of PSA, prostatic volume and Neutrophil/ Lymfocyte ratio (Ne/Ly ratio), in predicting prostatic cancer, we have evaluated 113 men, mean age 67,9+/-5,85 years, all of them with symptoms for prostatic enlargement. The patients had frequent urination, dysuric problems, difficulty starting urination, a weak or slow urinary stream, feeling of incomplete bladder emptying, urgency to urinate and getting up frequently at night to urinate. In all of the patients, prostatic biopsy was performed. We have analysed prostatic volume, PSA and Neutrophil/lymphocyte ratio in all of them, but after that we have divided them in 2 groups depending histopathologic finding from the biopsy. First group were patients with benign prostatic hyperplasia (BPH) and the second one were patients with prostatic cancer (PC).
Results. 68 out of 113 patients were with BPH, mean age 66.9+/-5.8 years and 45 patients were with carcinoma prostatae, mean age 69.3+/-5.5years. There was statistically significant difference between the age of the groups (p=0.034). The values of PSA were also statistically different: in patients with BPH were 30,8 +/-38,4 and in patients with PC 53.6+/-59ng/ml (p=0.014). The volume calculated with echosonography was also statistically different: in patients with BPH 65.3+/-28.8 cm^3 and in patients with CP 45.9+/-21.3 cm^3 (P=0.000). For Ne/ Ly ratio (NLR), we found difference between the 2 groups, but it was not statistically significant (p=0.678).
Conclusion. In conclusion the authors confirmed the diagnostic values of PSA and prostatic volume for predicting prostatic cancer, but the value for Ne/Ly ratio was not found predictive for diagnosis of prostatic cancer.

Keywords: prostatic volume, PSA, Ne/Ly ratio, prostatic cancer

Introduction

Prostatic cancer (PC) is one of the most frequently diagnosed cancers and a main cause of cancer deaths in men [1,2]. Screening of prostate-specific antigen (PSA) has contributed to the detection of PC at an early stage, but PC is still frequently diagnosed for the first time already at an advanced stage [2,3]. Although the level of PSA above 4 ng/ml, is sign for presence of PC, benign prostatic hyperplasia (BPH) is frequently accompanied with higher levels of PSA. The neutrophil-to-lymphocyte ratio (NLR) is one factor that has been widely reported to be a prognostic factor not only in PC but also in some solid cancers [3-7]. NLR inflammation markers in PC and BPH are also reported as marker for diagnosis of PC. The aim of the current study is to evaluate the diagnostic values of PSA, prostatic volume and Ne/Ly ratio in predicting PC.
A normal range of NLR is between 1-2, the values higher than 3.0 and below 0.7 in adults are pathological. NLR in a grey zone between 2.3-3.0 may serve as an early warning of pathological state or process such like cancer, atherosclerosis, infection, inflammation, psychiatric disorders and stress.

Material and methods

In order to find the diagnostic method for predicting prostatic cancer, we have evaluated 113 men, mean age 67.9+/-5.85 years, all of them with symptoms of prostatic enlargement. The patients had frequent urination, dysuric problems, difficulty starting urination, a weak or slow urinary stream, feeling of incomplete bladder emptying, urgency to urinate and getting up frequently at night to urinate. Echosonograhic investigation was performed, and found enlargement of the prostatic gland. In all patients, prostatic biopsy was performed. We have analysed prostatic volume and PSA in all of them, but after that we have divided them in 2 groups depending on histopathologic finding from

Correspondence to: Vesna Ristovska, University Clinic for Nephrology, Medical Faculty, University St. Cyril and Methodius, 1000 Skopje. R. N. Macedonia; E-mail: v.ristovska@yahoo.com

the biopsy. First group were patients with BPH and the second group were patients with PC.

In the present study, we evaluated also the role of NLR in men who underwent prostate needle biopsy for their initial diagnosis of PC. Both, complete blood counts and PSA ratio were examined in a total of 113 men in our institution. Of these, 68 patients (60%) had BPH and 45 patients (40%) who subsequently underwent prostate needle biopsy were found to have prostatic adenocarcinoma.

To derive a more precise estimate of the prognostic significance of the NLR, in this study, we performed a systematic review of the most recently published studies.

Although PSA has a good sensitivity, the test suffers from low specificity, due to the difficulty in distinguishing patients with PC versus benign prostatic conditions. Other data show that men with a false positive PSA at screening, are more likely to develop prostate cancer during the follow-up. Furthermore, an invasive biopsy may miss cancer in some men, up to 20% of men will be found to have prostate cancer on a repeated biopsy [8].

Chronic inflammation is involved in the development and progression of invasive and metastatic bladder cancer [9]. Immune cells play multifaceted roles in the tumor microenvironment via dynamic and extensive communication with cancer cells [10]. Neutrophils can contribute to chronic inflammation and promote tumor angiogenesis and growth by secreting specific molecules [9,11].

Results

The parameters of all of the patients undergoing prostatic biopsy are as follows and they are presented at table 1. Analysing the parameters of all patients underwent prostatic biopsy, we found that mean age of the patients was 67.9+/-5.85 years. PSA was 22.55+/-41.01, prostatic volume was 57.62+/-27.73 cm^3 and Ne/Ly ratio was 4.22 +/-2.66. This value for Ne/Ly ratio is higher than normal range, which means that some pathological state or process is going on, such as inflammation or cancer.

After presenting all patients that underwent prostatic biopsy, we divided them in 2 groups depending on the result of prostatic biopsy. First group were patients with BPH and the second patients with PC.

Table 1. Values of the parameters in patients with prostatic biopsy

No=113	X	SD
Age (years)	67.90	5.85
PSA (ng/ml)	22.55	41.04
Volume (cm^3)	57.62	27.73
Hb (g/L)	138.07	13.28
Er (10^{12}/L)	4.71	0.61
Htc (L/L)	0.42	0.04
Le ($x10^9$/L)	7.90	3.32
Ly ($x10^9$/L)	1.51	0.55
Ne ($x10^9$/L)	5.72	3.18
NLR	4.22	2.66
Mo ($x10^9$/L)	0.61	0.26
Tr ($x10^9$/L)	216.71	66.68

Table 2. Difference between the parameters in patients with BPH and PC

Parameters	BPH		Carcinoma		p
	X	SD	X	SD	
	No=68		No=45		
Age (years)	66.96	5.87	69.33	5.58	0.034
PSA (ng/ml)	30.83	38.45	53.62	59.02	0.014
Volume(cm^3)	65.37	28.88	45.91	21.32	0.000
Hb g/l	139.27	14.00	135.60	11.54	0.260
Er ($x10^{12}$/L)	4.78	0.68	4.57	0.41	0.150
Htc (L/L)	0.42	0.05	0.41	0.04	0.168
Le ($x10^9$/L)	8.16	3.79	7.40	2.02	0.353
Ly ($x10^9$/L)	1.52	0.57	1.49	0.54	0.808
Ne ($x10^9$/L)	5.99	3.60	5.18	2.04	0.300
NLR	4.28	2.49	4.01	4.01	0.270
Mo ($x10^9$/L)	0.64	0.26	0.55	0.26	0.154
Tr ($x10^9$/L)	214.65	71.52	220.92	56.63	0.703

Table 2 is showing the differences between the parameters in patients with BPH and PC. 68 out of 113 patients were with BPH, mean age 66.9+/-5.8years and 45 patients were with PC, mean age 69.3+/-5.5years. There is statistically significant difference between the groups (p=0.034). The values for PSA were also statistically different: in patients with BPH were 30.8+/-38.4 ng/ml and in patients with PC 53.6+/-59 ng/ml (p=0.014). The volume calculated with echosonography is also statistically different: in patients with BPH 65.3+/-28.8 cm^3 and in patients with CP 45.9+/-21.3 cm^3 (P=0.000). For Ne/ Ly ratio, we found difference between the 2 groups, but it was not statistically significant (p=0.678).

Table 3. Predictors of prostatic cancer

Predictors of Ca prostatae	OR	95%CI	95%CI	P
Age (years)	1.093	0.915	1.307	0.328
PSA (ng/ml)	1.253	1.049	1.497	0.014
Volume (cm^3)	0.697	0.583	0.833	0.000

Considering this fact, we can say that age, PSA values and prostatic volume are statistically different in patients with BPH compared to those with PC.
The PSA and prostatic volume were the independent predictors of PC, which is presented on the Table 3.
We have also analysed the difference between the 2 groups of patients, with PSA>5 and PSA<5. The difference between the 2 groups of patients, considering the PSA values (PSA>5 and PSA<5) were shown on Table 4. In patients with PSA>5, Neutrophils were 5.24+/-1.6, but in patients with PSA<5, were 9.58+/-6.95. The difference is statistically significant (p=0,000). The values for Neutrophyl-to-Lymfocyte ratio are also differrent. In patients with PSA>5, Ne/Ly ratio was 4.11+/-2.31 and in patients with PSA<5, Neutrophil-to-Lymphocyte ratio was 6.37+/-5.7, with statistical significance (p=0,000).

Table4. The difference between the 2 groups depending on PSA values

	PSA>5		PSA< 5		
Parameters	**X**	**SD**	**X**	**SD**	**p**
Age (years)	67.72	6.15	66.22	3.15	0.475
PSA (ng/ml)	24.67	42.83	3.97	0.79	0.153
Volume(cm^3)	58.62	29.68	54.56	17.19	0.689
Hb g/l	139.62	12.40	146.50	13.28	0.206
Er ($x10^{12}$/L)	4.69	0.51	5.42	1.02	0.005
Htc (L/L)	0.42	0.04	0.45	0.04	0.070
Le ($x10^9$/L)	7.35	1.65	11.88	6.76	0,000
Ly ($x10^9$/L)	1.43	0.48	1.70	0.51	0.197
Ne ($x10^9$/L)	5.24	1.60	9.58	6.95	0.000
NLR	4.11	2.31	6.37	5.70	0.000
Mo ($x10^9$/L)	0.60	0.28	0.60	0.06	0.972
Tr ($x10^9$/L)	205.98	57.21	256.33	103.98	0.068

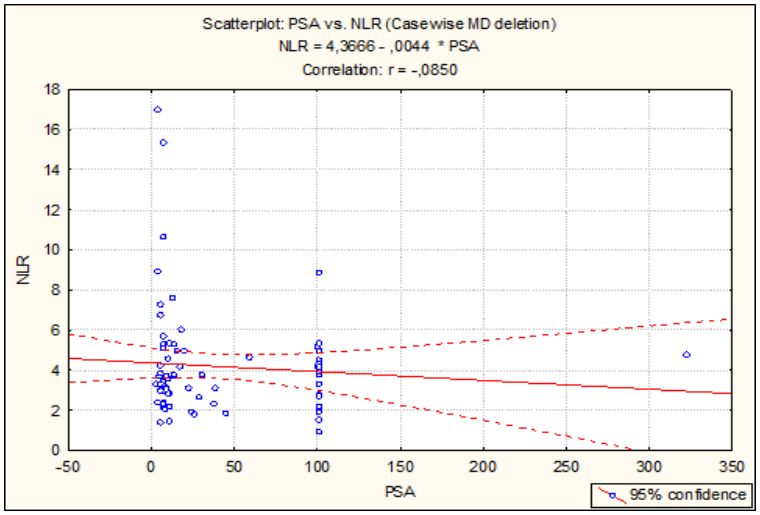

Fig. 1. The correlation between PSA and Ne/Ly ratio. P=0,465

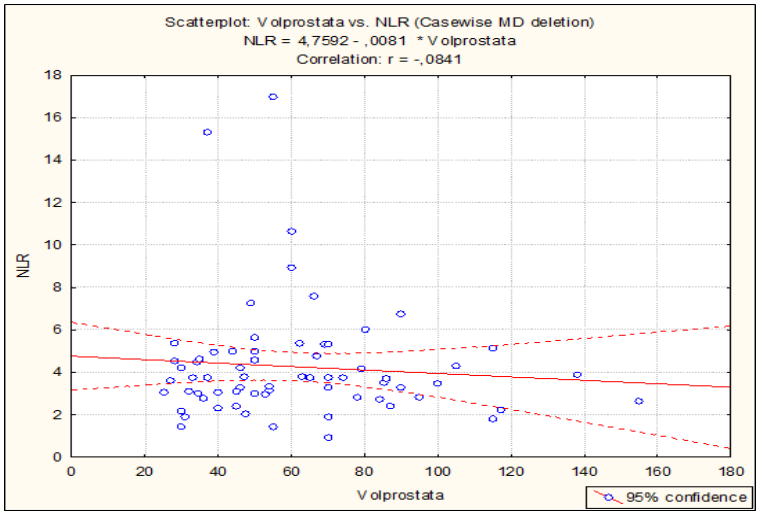

Fig. 2. The correlation for the prostatic volume vs.Ne/Ly ratio. P=0,499

As we found that PSA and prostatic volume are predictors of the PC, we have evaluated the correlation with Ne/Ly ratio, which is presented at Figure 1.
The correlation between PSA and Ne/Ly ratio is presented on Figure1, and the correlation for the prostatic volume vs.Ne/Ly ratio is shown on Figure 2.

Discussion

Prostate cancer is the most common malignancy in men. The PSA screening test is widely available, but a large number of patients still present advanced stage prostate cancer. PSA was also positively correlated with the NLR in patients with PC [8,12]. The association of NLR with higher serum PSA levels might indicate impairment in the adaptive host's ability to control the inflammation [13]. Sometimes the lower Ne/Ly ratio shows the stage of decreased inflammation. The PSA level was shown to be a prognostic factor in the PC patients with a PSA of >500 ng/mL, and higher PSA levels (>1000 or 5000 ng/mL) were associated with a poorer outcome [14]. Our results also support those data.
NLR can be easily calculated from the routine complete blood counts in peripheral blood. NLR has been suggested as not only a predictor of systemic inflammatory response in critical care patients but also a prognosticator for some solid malignancies including PC [15-24]. Men with elevated serum PSA yet without the diagnosis of PC were found to have a higher NLR compared with those with a normal PSA level [25], suggesting that certain markers of systemic inflammation and/or immune system activation were associated with an elevated serum PSA.
There was also statistical difference for the age between the 2 group of patients (p=0.034). The values of PSA and prostatic volume were statistically different between the 2 group of patients (p=0.014 and p=0.000, respectively).
A PSA test provides useful information, not only for the screening of PC but also for the monitoring of the follow-up treatment. Moreover, PSA monitoring before and after treatment, are useful to evaluate the response of treatment in patients with PC. PSA concentrations decrease by 80% in approximately 80% of patients in the first month [26,27].
Furthermore, an invasive biopsy may miss cancer in some men, given up to 20% of men will be found to have PC on the repeated biopsy [8,28]. NLR was shown to positively correlate with the elevated serum PSA [8].
An NLR cutoff of ≥5 is most commonly used to define abnormal elevation in the metastatic setting. Patients with cancer and an NLR above the defined cutoff have consistently been found to have worse outcomes than patients with a lower NLR across cancer types [29-31].
Several studies have investigated the relationship between the neutrophil-to-lymphocyte ratio (NLR) and prostate-specific antigen (PSA) levels in patients with prostate cancer, aiming to understand their combined prognostic value.
NLR alone is not with a possibility for definitive conclusion and although useful, NLR should not be used as a standalone diagnostic tool. It may be combined with PSA, imaging (e.g., MRI), and histopathological findings. Our results also support this conclusion.
Factors such as infections, medications, and other inflammatory conditions can affect NLR levels. Since BPH is also associated with chronic inflammation, NLR may be slightly elevated in these patients, but not as much as in prostatic cancer. This is because systemic inflammation is more pronounced in malignancies.
Some inflammatory cytokine markers, including the NLR, monocyte-lymphocyte ratio (MLR), and platelet-to-lymphocyte ratio, play important roles as prognostic markers in certain solid malignancies, including PC [27,28,32]. We also, previously reported the NLR to be a poor prognostic marker for other carcinomas, which is confirmed in other references [32-34]. In prostate cancers, the higher NLR group showed a higher incidence of PC among patients whose PSA was 4-10 ng/ml. A higher NLR was also associated with a poorer overall survival. NLR is easily calculated using complete blood cell counts (CBCs) which was widely measured in daily clinical practices. Thus, previous data was easily obtained in each patient, i.e. each prostate cancer progression stage at no additional cost as requirement.
Inflammatory response was seen in many cases in urological malignancy [35,36].

Conclusion

In conclusion, we can say that NLR is important marker for diagnosis and treatment of PC, but predictors for PC are still the PSA and prostatic volume. The authors confirmed the diagnostic values for PSA and prostatic volume for predicting prostatic cancer, but the value for Ne/Ly ratio is not predictive for diagnosis of prostatic cancer. Our investigation confirms the relationship between the NLR and PSA levels in patients with prostate cancer, aiming to understand their combined prognostic value.

Conflict of interest statement. None declared.

References

1. Siegel RL, Miller KD, Jemal A. Cancer statistics, 2015. *CA Cancer J Clin* 2015; 65: 5-29.
2. Masato Yasui, Yoriko Hasegawa, Takashi Kawahara, *et al*. Baseline neutrophil-to-lymphocyte ratio predicts the prognosis of castration-resistant prostate cancer treated with abiraterone acetate. *Mol Clin Oncol* 2018; 8(4): 587-591.
3. Cao J, Zhu X, Zhao X, *et al*. Neutrophil-to-lymphocyte ratio predicts psa response and prognosis in prostate cancer: A

systematic review and meta-analysis. *PLoS One* 2016; 11:(7): e0158770.
4. Kawahara T, Yokomizo Y, Ito Y, *et al*. Pretreatment neutrophil-to-lymphocyte ratio predicts the prognosis in patients with metastatic prostate cancer. *BMC Cancer* 2016; 16: 111.
5. Langsenlehner T, Thurner EM, Krenn-Pilko S, *et al*. Validation of the neutrophil-to-lymphocyte ratio as a prognostic factor in a cohort of European prostate cancer patients. *World J Urol* 2015; 33: 1661-1667.
6. Unlu O, Petekkaya E, Ozcan B, Altundag K. The association between neutrophil to lymphocyte ratio and survival in metastatic breast cancer patients. *J BUON* 2016; 21: 1322-1323.
7. Taguchi S, Nakagawa T, Matsumoto A, *et al*. Pretreatment neutrophil-to-lymphocyte ratio as an independent predictor of survival in patients with metastatic urothelial carcinoma: A multi-institutional study. *Int J Urol* 2015; 22: 638-643.
8. McDonald AC, Vira MA, Vidal AC, *et al*. Association between systemic inflammatory markers and serum prostate-specific antigen in men without prostatic disease - the 2001-2008 National Health and Nutrition Examination Survey. *The Prostate* 2014; 74: 561-567.
9. Thompson DB, Siref LE, Feloney MP, *et al*. Immunological basis in the pathogenesis and treatment of bladder cancer. *Expert Rev Clin Immunol* 2015; 11: 265-279.
10. Grivennikov SI, Greten FR, Karin M. Immunity, Inflammation, and Cancer. *Cell* 2011; 140: 883-899.
11. Jackaman C, Tomay F, Duong L, *et al*. Aging and cancer: The role of macrophages and neutrophils. *Ageing Res Rev* 2017; 36: 105-116.
12. Minardi D, Scartozzi M, Montesi L, *et al*. Neutrophil-to-lymphocyte ratio may be associated with the outcome in patients with prostate cancer. *Springerplus* 2015; 4: 255.
13. Sugihara T, Yu C, Kattan MW, *et al*. Long-term survival of extremely advanced prostate cancer patients diagnosed with prostate-specific antigen over 500 ng/ml. *Jpn J Clin Oncol* 2014; 44(12): 1227-1232.
14. Xue P, Kanai M, Mori Y, *et al*. Neutrophil-to-lymphocyte ratio for predicting palliative chemotherapy outcomes in advanced pancreatic cancer patients. *Cancer medicine* 2014; 3: 406-415.
15. Gomez D, Morris-Stiff G, Toogood GJ, *et al*. Impact of systemic inflammation on outcome following resection for intrahepatic cholangiocarcinoma. *Journal of surgical oncology* 2008; 97: 513-518.
16. Chua W, Charles KA, Baracos VE, Clarke SJ. Neutrophil/lymphocyte ratio predicts chemotherapy outcomes in patients with advanced colorectal cancer. *British journal of cancer* 2011; 104: 1288-1295.
17. Azab B, Bhatt VR, Phookan J, *et al*. Usefulness of the neutrophil-to-lymphocyte ratio in predicting short- and long-term mortality in breast cancer patients. *Annals of surgical oncology* 2012; 19: 217-224.
18. Dalpiaz O, Pichler M, Mannweiler S, *et al*. Validation of the pretreatment derived neutrophil-lymphocyte ratio as a prognostic factor in a European cohort of patients with upper tract urothelial carcinoma. *British journal of cancer* 2014; 110: 2531-2536.
19. Jung MR, Park YK, Jeong O, *et al*. Elevated preoperative neutrophil to lymphocyte ratio predicts poor survival following resection in late stage gastric cancer. *Journal of surgical oncology* 2011; 104: 504-510.
20. Demirtas A, Sabur V, Akinsal EC, *et al*. Can neutrophil-lymphocyte ratio and lymph node density be used as prognostic factors in patients undergoing radical cystectomy? *TheScientificWorldJournal* 2013; 2013: 703579.
21. Walsh SR, Cook EJ, Goulder F, *et al*. Neutrophil-lymphocyte ratio as a prognostic factor in colorectal cancer. *Journal of surgical oncology* 2005; 91: 181-184.
22. Ohno Y, Nakashima J, Ohori M, *et al*. Pretreatment neutrophil-to-lymphocyte ratio as an independent predictor of recurrence in patients with nonmetastatic renal cell carcinoma. *The Journal of urology* 2010; 184: 873-878.
23. Bartlett EK, Flynn JR, Panageas KS, *et al*. High Neutrophil to Lymphocyte Ratio (NLR) is Associated with Treatment Failure and Death in Melanoma Patients Treated with PD-1 Inhibitor Monotherapy. *Cancer* 2020; 126(1): 76-85.
24. Rosenberg L, Lawlor GO, Zenlea T, *et al*. Predictors of endoscopic inflammation in patients with ulcerative colitis in clinical remission. *Inflammatory bowel diseases* 2013; 19: 779-784.
25. Arai Y, Yoshiki T, Yoshida O. Prognostic significance of prostate specific antigen in endocrine treatment for prostatic cancer. *J Urol* 1990; 144: 1415-1419.
26. Matzkin H, Eber P, Todd B, *et al*. Prognostic significance of changes in prostate-specific markers after endocrine treatment of stage D2 prostatic cancer. *Cancer* 1992; 70: 2302-2309.
27. Yuksel OH, Urkmez A, Akan S, *et al*. Predictive Value of the Platelet-To-Lymphocyte Ratio in Diagnosis of Prostate Cancer. *Asian Pac J Cancer Prev* 2015; 16(15): 6407-6412.
28. Kilpelainen TP, Tammela TL, Roobol M, *et al*. False-positive screening results in the European randomized study of screening for prostate cancer. *European journal of cancer* 2011; 47: 2698-2705.
29. De Marzo AM, Platz EA, Sutcliffe S, *et al*. Inflammation in prostate carcinogenesis. *Nature reviews Cancer* 2007; 7: 256-269.
30. Shafique K, Proctor MJ, McMillan DC, *et al*. Systemic inflammation and survival of patients with prostate cancer: evidence from the Glasgow Inflammation Outcome Study. *Prostate cancer and prostatic diseases* 2012; 15: 195-201.
31. Ploussard G, Nicolaiew N, Marchand C, *et al*. Risk of repeat biopsy and prostate cancer detection after an initial extended negative biopsy: longitudinal follow-up from a prospective trial. *BJU international* 2013; 111: 988-996.
32. Kawahara T, Fukui S, Sakamaki K, *et al*. Neutrophil-to-lymphocyte ratio predicts prostatic carcinoma in men undergoing needle biopsy. *Oncotarget* 2015; 6(31): 32169-32176.
33. Mochizuki T, Kawahara T, Takamoto D, *et al*. The neutrophil-to-lymphocyte ratio (NLR) predicts adrenocortical carcinoma and is correlated with the prognosis. *BMC Urol* 2017; 17(1): 49.
34. Kawahara T, Yokomizo Y, Ito Y, *et al*. Pretreatment neutrophil-to-lymphocyte ratio predicts the prognosis in patients with metastatic prostate cancer. *BMC Cancer* 2016; 16: 111.
35. Ohno Y. Role of systemic inflammatory response markers in urological malignancy. *Int J Urol* 2019; 26(1): 31-47.
36. Hao Peng, Xiaogang Luo. Prognostic significance of elevated pretreatment systemic inflammatory markers for patients with prostate cancer: a meta-analysis *Open Access* Published: 25 March 2019.

BANTAO Journal 2023; 22(2): 37-40

BJ
BANTAO Journal

Case Report

A Case of Persistent Microscopic Hematuria with Associated Proteinuria - Not Your Usual Suspect

Gabriela Fibia Chichinesdi[1], Iulia Grosu[1,2], Adrian Vaduva[3], Felix Maralescu[1,2], Madalina Bodea[1,2] and Flaviu Raul Bob[1,2]

[1]Department of Internal Medicine II -Nephrology University Clinic, "Victor Babes" University of Medicine and Pharmacy Timisoara, County Emergency Hospital Timisoara, [2]Centre for Molecular Research in Nephrology and Vascular Disease, Faculty of Medicine, "Victor Babes" University of Medicine and Pharmacy, Timisoara, [3]Department of Microscopical Morphology-Morphopathology ANAPATMOL CMC, "Victor Babes" University of Medicine and Pharmacy, Timisoara, Romania

Abstract

IgM nephropathy has been described as a distinct glomerulopathy characterized by the presence of IgM deposits in immunofluorescence. Its presentation is usually associated to nephrotic syndrome, and not so often with subnephrotic proteinuria or hematuria. Most often it affects children and young adults. This clinical case outlines the evaluation of a nephritic syndrome - a 51-year-old woman with essential hypertension for 30 years and persistent microscopic hematuria for 6 months. Besides the complete laboratory workup specific for glomerulopathies, the case required a kidney biopsy in order to establish the etiology of the nephritic syndrome. After confirming the diagnosis of IgM nephropathy, an angiotensin 2 receptor blocker and a sodium-glucose cotransporter-2 inhibitor (SGLT2i) were introduced for symptom control, with a favorable outcome and complete remission of proteinuria and albuminuria. The particularity of the case is that even if clinical presentation suggested an IgA nephropathy (the most frequent presentation with a similar clinical picture), kidney biopsy eventually indicated an IgM nephropathy, a much rarer entity.

Keywords: nephritic syndrome, IgM nephropathy, microscopic hematuria

Introduction

From an epidemiological point of view, the prevalence of IgM Nephropathy (IgMN) ranges from 2% to 18.5% [1]. It is often associated with systemic disorders including systemic lupus erythematosus, rheumatoid arthritis, diabetes mellitus, Sjogren syndrome, Alport's syndrome etc. [2].

The pathogenesis of IgM nephropathy is still uncertain, most theories advocating T-cell abnormalities with stimulation of cytotoxic T-cells and down-regulation of regulatory T-cells [1] or an ineffective clearance by mesangial cells [3]. Others propose the hypothesis of an immune complex disease with activation of the immune complement pathway [4], as suggested by the consistent appearance of C1q, and C4 in the glomerular mesangium [5]. Antigens that trigger immune complex formation are thought to be specific antigens found in food or the environment [1]. Certain studies indicate that the female gender and those presenting with hematuria tend to have a more favorable outcome, suggesting that genetic factors may play a role in the development of this pathology. [6].

Regarding IgM deposits at IF, the distribution is present in all glomeruli in a diffuse manner and it affects the whole glomerulus in a global disposition [7]. This particular pathological aspect can be found in minimal change disease (MCD), focal segmental glomerulosclerosis (FSGS), and mesangial proliferative glomerulonephritis [8], however, it is now agreed that it represents a distinct entity with a greater resistance to steroids and worse prognosis compared with MCD [3]. Compared to FSGS, which usually recurs early in the renal graft, there are fewer cases of IgM nephropathy recurrence post-transplantation [9].

To diagnose IgM nephropathy on kidney biopsy, Connor *et al*., proposed a number of criteria: prevalent staining for IgM by immunofluorescence, with an intensity more than trace, distributed in the mesangium; IgG and IgA should not be equal or higher in intensity than IgM-i.e. IgM should be dominant; with obvious mesangial deposits on EM [10]. In their study, Connor *et al*., concluded that the histological finding most often linked with progressive renal impairment was segmental sclerosis affecting >20% of glomeruli. Interstitial fibrosis and

Correspondence to: Gabriela Fibia Chichinesdi, Department of Internal Medicine II -Nephrology University Clinic, "Victor Babeș" University of Medicine and Pharmacy Timisoara, County Emergency Hospital Timisoara, Romania; E-mail: fibia.chichinesdi@yahoo.com

tubular atrophy involving more than 20% of the biopsy specimen are also associated with kidney dysfunction [10]. IgM nephropathy often presents with nephrotic syndrome. A study by Ghadeer A Mokhtar found that, from a total of 36 patients examined, the initial presentation was nephrotic syndrome in 32 patients, proteinuria in two, and hematuria coupled with proteinuria in 16 [3]. Rarely, IgM nephropathy can display as rapidly prog ressive glomerulonephritis (RPGN).

Case presentation

A 51-year-old female patient known with essential hypertension for 30 years and treated with lercanidipine and nebivolol was recently diagnosed with a left adrenal adenoma, hepatomegaly, and a bicornuate uterus, otherwise no other known pathologies, presented at the Nephrology outpatient clinic for persistent microscopic hematuria for six months. Three months prior to the presentation, she underwent blood and urine tests with the following results (Table 1).

Table 1. Laboratory parameters before presentation

Parameters	May	June
\Creatinine (mg/dl)	1.13	
eGFR (ml/min/1.73 m^2)	59	
24h proteinuria (g/24h)	1.1	0.67
Addis sediment count Leukocytes (/min)	3878	
Addis sediment count RBCs (/min)	28254	

Abbreviation: eGFR - estimated glomerular filtration rate; RBCs - red blood cell count

On admission, clinical examination revealed light pitting edema, blood pressure 140/80 mmHg, and a heart rate of 80 bpm. To establish the cause of the nephritic syndrome, an extensive panel of laboratory tests was performed, including serum total protein, serum albumin, UACR, complement levels (normal levels), and serum immunoglobulin levels (normal values). Viral markers and anti-nuclear antibodies (ANA) for infectious and immunological causes, respectively, were ordered-normal results. Urinalysis and Addis sediment count were also repeated. The most relevant results are shown below (Table 2).

Table 2. Laboratory parameters at the time of presentation

Parameters	August
Creatinine (mg/dl)	1.07
eGFR (ml/min/1.73 m^2)	63
24h proteinuria (g/24h)	0.34
Addis sediment count Leukocytes (/min)	900
Addis sediment count RBCs (/min)	900
UACR (mg/g)	340

Abbreviation: UACR - urine albumin-creatinine ratio

A kidney biopsy was performed. Out of 13 glomeruli examined, the kidney biopsy depicted one glomerulus with segmental sclerosis and two with complete sclerosis. Minimal expansion of the mesangial matrix was detected, along with red blood cell casts, interstitial hemorrhage, rare atrophic tubules, and small areas of interstitial fibrosis. Immunofluorescence studies showed strong granular staining for IgM within the mesangial area and some minimal deposits of IgA, establishing the diagnosis of IgM nephropathy.

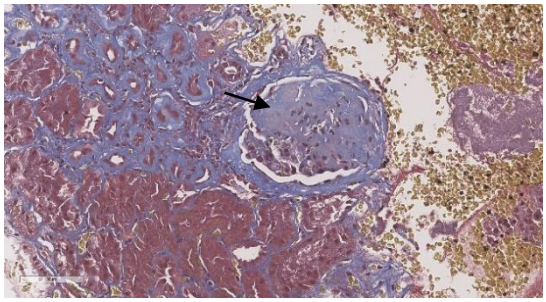

Fig. 1. Masson's trichrome showing segmental sclerosis

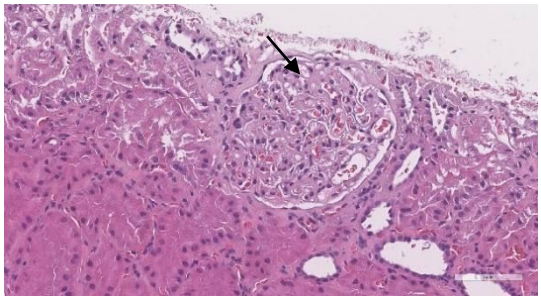

Fig. 2. Hematoxylin and eosin revealing minimal expansion of the mesangial matrix

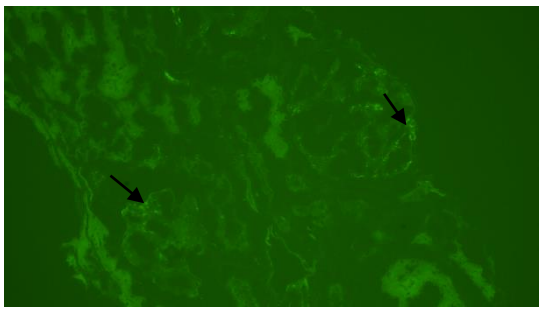

Fig. 3. Immunofluorescence with IgM deposits

There are no specific guidelines yet regarding the treatment of IgM nephropathy. The management of the case was to introduce an angiotensin 2 receptor blocker and a sodium-glucose cotransporter-2 inhibitor (SGLT2i) in order to control hypertension and elevated proteinuria. As recommended, the first approach to management is to treat the underlying pathology (which is not really feasible in this case with an unknown etiology) and then control risk factors for the progression of CKD, especially hypertension, which causes glomerular hyperfiltration and proteinuria [11]. Four months later, serum creatinine was 1.08 mg/dl, with proteinuria levels decreased to 0,26 g/24h. The urine albumin-creati-

nine ratio dwindled from 340 mg/g in August to 77 mg/g in December.

Apart from the antihypertensive effect, angiotensin 2 receptor blockers have a number of benefits. The renal vasodilatation they produce can help prevent renal ischemia and hypoxia; by lowering intraglomerular pressure, they lower urinary albumin excretion [12]. As for SGLT2i, the DAPA-CKD trial showed reduced albuminuria by 26% and a diminished risk by 71% of major adverse kidney events with dapagliflozin compared to the control group in patients with IgA nephropathy [13]. It has been demonstrated that SGLT2i, through increased delivery of sodium, chloride, and water to the macula densa, causes vasodilation in the afferent arterioles, reducing intraglomerular pressure and thus decreasing urinary protein excretion [13].

If the patient does not respond to the above treatment, other treatment options would be glucocorticoids and immunosuppressive agents. Studies have shown a mean resistance of 28% at corticosteroids, proving that IgM nephropathy has a less effective response to steroids than MCD (minimal change disease) [6]. Among the immunosuppressive agents, cyclosporine and anti-CD antibodies (rituximab) could constitute a treatment option. IgM nephropathy can also present as an immune complex-mediated crescentic GN, with nephrotic-range proteinuria, as reported by Park K *et al*., In such cases, much more aggressive treatment is needed, such as Rituximab [14].

Table 3. Laboratory parameters after treatment

Parameters	August	December
Creatinine (mg/dl)	1.07	1.08
eGFR (ml/min/1.73 m^2)	63	62
24h proteinuria (g/24h)	0.34	0.26
Stansfeld Webb -urine Leukocytes (/μL)		0
Stansfeld Webb -urine RBCs (/μL)		7.5
UACR (mg/g)	340	77

Discussion

Most cases of IgMN documented until now are associated with nephrotic syndrome, many of them resistant to steroids. However, this type of pathology may present with hematuria coupled with proteinuria, as is the case described above. The proteinuria level of our patient was not extremely high at presentation-1.1 g/24h-however it responded well to the antiproteinuric treatment, falling to 0.26 g/24h six months later. Another presentation is with hematuria as the only sign-described mainly in female patients [3].

In rare cases, IgM nephropathy can present with rapidly progressive glomerulonephritis (RPGN) as descrybed by Kazi and Mubarak in the case of an 11-year-old female who presented with sudden generalized body swelling, anorexia, and moderate hearing loss. Her blood and urinary tests revealed 1+ albumin, 15-20 white blood cells (WBCs)/HPF and 6-8 red blood cells (RBCs)/HPF, blood urea 198 mg/dL and serum createnine 4.5 mg/dL. She was treated with three pulses of methylprednisolone followed by oral steroids, her serum creatinine falling to 2.3 mg/dl [16].

Though the studies regarding IgM nephropathy treatment are not so many, Bagchi *et al*., studied the RAS (renin-angiotensin system) blockade with an ACEi (angiotensin-converting enzyme inhibitor) or an ARB (angiotensin receptor blocker) in IgMN with a follow-up of 6 months, to investigate on proteinuria remission. Remission was obtained in 36.5% of patients at 3 months and 55.2% at 6 months [15].

As for the natural history of the pathology, up to 25% of followed-up cases progressed to end stage renal disease (ESRD) [17]. It is also frequent for IgM nephropathy to develop in later stages into FSGS [6], as many repeated biopsies done in patients with worsening kidney function or recurrence of nephrotic syndrome had typical histological aspects of FSGS [14]. In the study done by Myllymäki *et al*., 36% of patients progressed to renal failure, 23% advanced to ESRD, and from the 35% with hypertension at the time of biopsy, the percentage rose up to 45% at the end of the study [6].

Wesphal S *et al*., describe the recurrence of nephrotic syndrome in a transplanted 15-year-old boy, with proteinuria levels at 20 g/L after three days and doubled values of serum creatinine from baseline. The treatment consisted of plasma exchanges, thymocyte globulin, steroids, and also a dose of rituximab. After 5 months, proteinuria was resolved, and the serum creatinine level normalized. [9]

Among histological data, Connor *et al*., identified glomerular sclerosis and tubular atrophy as factors contributing to kidney dysfunction, with focal segmental glomerulosclerosis present in 80% of individuals who underwent another kidney biopsy [10].

Conclusions

This report highlights a clinical and biological presentation of a primitive IgMN with a favorable response to a conservative therapy and no need for immunosuppressive treatment. This is particularly relevant given the heterogeneous case presentations described in the available literature.

Conflict of interest statement. None declared.

Reference

1. Vanikar A. IgM nephropathy; can we still ignore it. *J Nephropathol* 2013; 2: 98-103.
2. Zabaneh I, Bandak D, Thammineni V. IgM glomerulonephritis. *Biomedical Research and Clinical Practice* 2018; 3(2): 1-2.

3. Mokhtar G. IgM Nephropathy-Clinical Picture and Pathological Findings in 36 Patients. *Saudi Journal of Kidney Dis and Transpl* 2011; 22(5): 969-975.
4. Hsu H, Chen W, Lin G, *et al*. Clinical and immunopathologic study of mesangial IgM nephropathy: report of 41 cases. *Histopathology* 1984; 8: 435-446.
5. Mubarak M, Kazi JI. IgM nephropathy revisited. *Nephrourol Mon* 2012; 4: 603-608.
6. Myllymaki J, Saha H, Mustonen J. IgM nephropathy: Clinical picture and long-term prognosis. *Am Journ of Kid Dis* 2003; 41: 343-350.
7. PubMed Central. Available online: https://pmc.ncbinlm.nih.gov/articles/PMC3614302/#A2805R1.
8. Meyrier A, Radhakrishnan J. Minimal change disease: Etiology, clinical features, and diagnosis in adults. https://www.uptodate.com/contents/minimal-change-disease-etiology-clinical-features-and-diagnosis-in-adults?search=igm%20nephropathy&source=search_result&selectedTitle=1%7E7&usage_type=default&display_rank=1#H263816993.
9. Westphal S, Hansson S, Mjörnstedt L, *et al*. Early recurrence of nephrotic syndrome (immunoglobulin M nephropathy) after renal transplantation successfully treated with combinations of plasma exchanges, immunoglobulin, and rituximab. *Transplant Proc* 2006; 38: 2659-2660.
10. Connor TM, Aiello V, Griffith M, *et al*. The natural history of immunoglobulin M nephropathy in adults. *Nephrol Dial Transplant* 2017; 32: 823-829.
11. Burnier M, Lin S, Ruilope L, *et al*. Effect of angiotensin receptor blockers on blood pressure and renal function in patients with concomitant hypertension and chronic kidney disease: a systematic review and meta-analysis. *Blood Pressure* 2019; 28: 358-374.
12. Kobori H, Mori H, Masaki T, Nishiyama A. Angiotensin II Blockade and Renal Protection. *Curr Pharm Des* 2013; 19: 3033-3042.
13. Dong Y, Shi S, Liu L, *et al*. Effect of SGLT2 inhibitors on the proteinuria reduction in patients with IgA nephropathy. *Front Med (Lausanne)* 2023; 10: 1242241.
14. Park K, Kang E, Kie J. A case report of immunoglobulin M nephropathy manifesting as crescentic glomerulonephritis and nephrotic syndrome in an adult. *BMC Neph* 2019; 20: 335.
15. Bagchi S, Mani K, Swamy A, *et al*. Supportive Management of IgA Nephropathy With Renin-Angiotensin Blockade, the AIIMS Primary IgA Nephropathy Cohort (APPROACH) Study. *Kidney International Reports* 2021; 6: 1661-1668.
16. Mubarak M, Kazi JI. IgM nephropathy presenting as full blown crescentic glomerulonephritis: first report in the literature. *Nefrologia* 2014; 34: 423-424.
17. O'Donoghue DJ, Lawler W, Hunt LP, *et al*. IgM-associated primary diffuse mesangial proliferative glomerulonephritis: natural history and prognostic indicators. *Q J Med* 1991; 79: 333-350.

BANTAO Journal 2023; 22(2): 41-45

BJ
BANTAO Journal

Case report

A Bleeding Threat: Intracystic Hemorrhage in Autosomal Dominant Polycystic Kidney Disease Leading to Nephrectomy – A Case Report

Blagica Pecanova Dungevska[1], Dajana Belokoska Blazeska[2], Njomza Bilali[3], Vlatko Karanfilovski[4], Angela Karafilovic[4], Mimoza Milenkova Bogojevska[4], Pavlina Dzekova Vidimliski[4] and Vesna Ristovska[4]

[1]General Hospital Strumica, [2]General Hospital Prilep, [3]Clinical Hospital Tetovo, [4]University Clinic of Nephrology, Medical Faculty, University Ss Cyril and Methodius, Skopje, Republic of North Macedonia

Abstract

Autosomal Dominant Polycystic Kidney Disease (ADPKD) is a common hereditary disorder characterrized by a progressive renal cyst formation, leading to chronic kidney disease (CKD) and end-stage renal disease (ESRD). A significant complication of ADPKD is intracystic hemorrhage, which can result in severe pain, hematuria, and anemia, often complicating disease management. We report the case of a 57-year-old female with a long-standing history of ADPKD and recurrent urinary infections. The patient initially presented with dysuria, fatigue, and fever, with a urine culture revealing Escherichia coli. Despite empirical antibiotic therapy, her condition deteriorated. She developed worsening kidney function, hematuria, and elevated inflammatory markers. Imaging studies, including ultrasound and CT urography, identified polycystic kidneys with suspected cyst infection and hemorrhage. Conservative treatment, including hydration, electrolyte supplementation, and parenteral antibiotics was initiated but failed to resolve symptoms. Due to persistent anemia, worsening renal function, and radiological evidence of intracystic hemorrhage, a left-sided nephrectomy was performed. After the surgery, clinical improvement was observed, with a decrease in CRP levels and stabilization of the hemoglobin. This case highlights the challenges in managing ADPKD-associated complications, particularly recurrent infections and hemorrhagic cysts. While conservative measures are the first-line approach, nephrectomy may be necessary in severe cases. Emerging therapies, such as vasopressin receptor antagonists, gene therapy, and regenerative medicine, have the potential to alter disease progression. An early diagnosis, close monitoring, and individualized treatment remain essential for optimizing outcomes in ADPKD patients.

Keywords: intracystic hemorrhage, nephrectomy, chronic kidney disease, polycystic kidney disease, cyst infection

Introduction

Adult Polycystic Kidney Disease also known as Autosomal Dominant Polycystic Kidney Disease (ADPKD), is a common hereditary disorder characterized by the progressive development of fluid-filled cysts in the kidneys. It is caused by mutations in the PKD1 or PKD2 genes, which encode proteins critical for maintaining normal tubular structure and function [1]. Over time, the expansion of these cysts leads to kidney enlargement, impairment of the renal function, and eventual chronic kidney disease (CKD) or end-stage renal disease (ESRD). ADPKD affects approximately 12.5 million individuals globally across all ethnicities. It accounts for up to 10% of cases of end-stage renal disease and poses a significant public health challenge [2]. A significant complication of APKD is hemorrhage into the renal cyst or the urinary tract. Cystic hemorrhage occurs due to the increased vascular fragility within the cyst walls, resulting from a pressure and vascular remodeling. Patients may present with gross hematuria, flank pain, or a sudden increase in abdominal or back pain, often accompanied by systemic symptoms like fever or anemia if the hemorrhage is extensive. Hemorrhagic complications can significantly impact the quality of life and may complicate disease management [3].

Case presentation

A 57-year-old female patient with a history of ADPKD has been regularly monitored for over 20 years at the University Clinic of Nephrology in Skopje. The patient reports recurrent urinary infections. She was hospitalized once in 2023 due to elevated inflammatory markers, positive urine sediment, and findings indicative of cyst infection,

Correspondence to: Vesna Ristovska, University Clinic for Nephrology, Medical Faculty, University St. Cyril and Methodius, 1000 Skopje. R. N. Macedonia; E-mail: v.ristovska@yahoo.com

with a positive urine culture for Enterococcus. She was discharged from the hospital with a serum creatinine level of 222 µmol/L (normal 45-109 µmol/L), indicating chronic kidney disease stage 4.

Currently, for the past month, the patient has been experiencing dysuria, fatigue and fever. The urine culture ordered by her primary care physician revealed *Escherichia coli* (1, 000, 000 CFU/ml). Antibiotic treatment with Ceftriaxone and Azithromycin was initiated, followed by fosfomycin for three days. Two weeks after the treatment, her general condition deteriorated again, with reduced appetite, hematuria and fever when Azithromycin was restarted. At the third day of treatment, laboratory findings showed serum creatinine 299 µmol/L, serum urea 13 mmol/L (normal range: 2.7-7.8 mmol/l), leukocytes $11x10^9$/L (normal range: 4-9 x 10^9/l), CRP 87 mg/L (normal <6 mg/l), with a positive urine sediment and the patient was hospitalized.

On physical examination, palpable, volumetrically enlarged kidneys and varicose veins in both lower legs were noted.

Ultrasound findings of the urinary tract revealed bilaterally enlarged, polycystic altered kidneys extending into the small pelvis, with numerous cystic formations of varying sizes. Among the cysts, a few smaller calculi and calcification in the walls were observed, which did not obstruct urodynamic. A suspicious cloudy cyst was noted in the lower part of the right kidney. In the middle segment of the left kidney, a cyst measuring 3,5x3 cm was filled with a dense content. Multiple cysts were also present in the liver. The urinary bladder was empty and not available for evaluation (Figure 1).

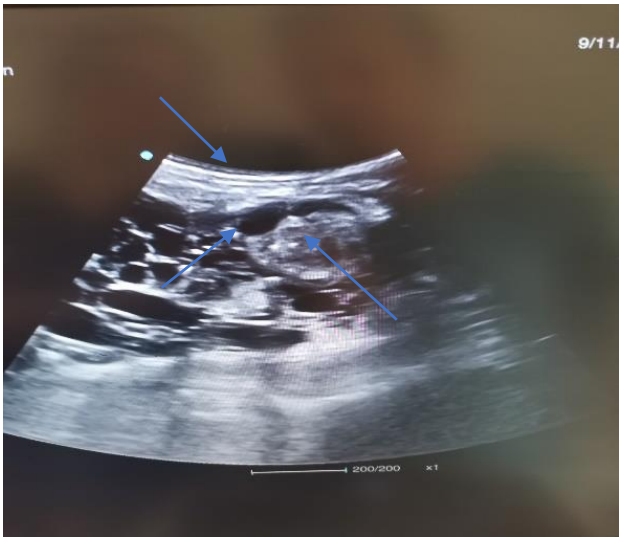

Fig. 1. Ultrasound imaging reveals a cystic formation containing echogenic material

The CT urography showed significantly enlarged kidneys with bilateral corticomedullary cysts, insufficient parenchyma and poor post-contrast imbibition and elimination of the administrated contrast. A small amount of fluid was noted in Douglas pouch (Figures 2A and 2B).

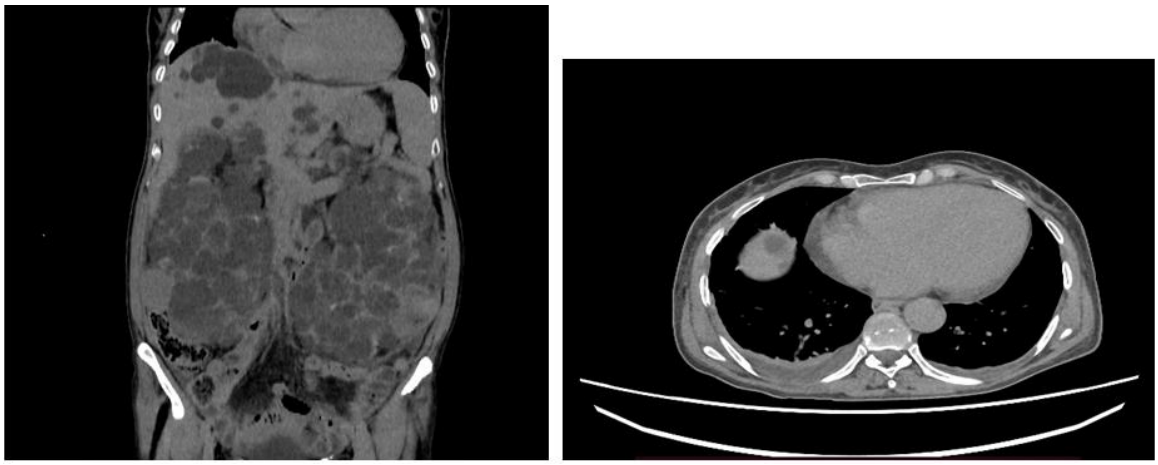

Fig. 2A and 2B. CT urography: Enlarged kidneys with cysts, poor contrast uptake and fluid in Douglas pouch

The patient was treated conservatively with hydration and electrolyte supplementation, achieving diuresis of up to 3400ml. The kidney function was stabilized without the need for hemodialysis. Throughout hospitalization, the patient experienced diffuse abdominal pain and high fever up to 38,2 °C, along with inflammatory markers and ultrasound findings suggestive of a left kidney cyst infection. Initial parenteral antibiotic therapy with ceftriaxone and amikacin was initiated and later switched to ciprofloxacin. Microbiological investigations (urine and blood culture) were sterile. The patient received pure blood transfusion. An urology consultation suggested infection or hemorrhage within the cyst. Due to persistent inflammatory markers despite the parenteral antibiotic therapy and worsening anemia with suspected cyst hemorrhage, further treatment continued at the Department of Urology.

Because of anemia, another CT urography was indicated, revealing significantly enlarged polycystic kidneys compressing adjacent abdominal and retroperitoneal structures. Hyperdense foci were detected within the cystic changes in the left kidney, with the largest

measuring 113x38 mm on axial scans and 163 mm on coronal scans. The density and lack of contrast enhancement changes were consistent with intracystic hemorrhage/hematoma. Both kidneys had minimal visible parenchyma with delayed and faint contrast enhancement. A small amount of low-density serous free fluid was observed in the Douglas pouch (Figures 3A and 3B).

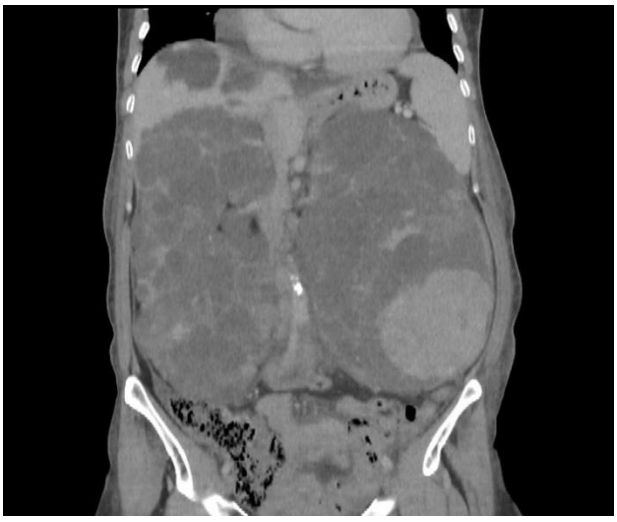

Fig. 3A. CT urography with enlarged polycystic kidneys and minimal visible parenchyma

The patient underwent a left-sided unilateral nephrectomy. Postoperative material sent to the pathology department showed the following macroscopic findings: the left kidney, encased in a scarce fibro-fatty capsule, weighed 2220 grams with dimensions 29x12x10 cm. Decapsulation was not possible. On sectioning, the renal parenchyma was replaced by numerous cysts, ranging in diameter from 0,2 to 4,5 cm. Some were filled

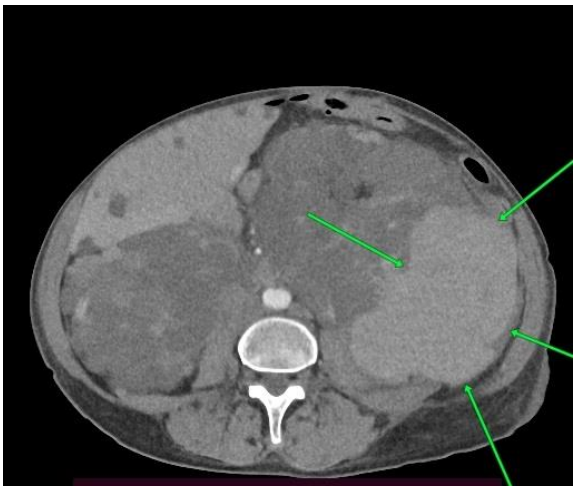

Fig. 3B. Hyperdense foci within the cystic changes in the left kidney

with clear yellow fluid, while others contained blood. Microscopic analysis revealed numerous cysts of varying size, lined with a cuboidal to flattened epithelium, with connective tissue septa in between. Some cysts contained hemorrhagic content, while others were empty or filled with proteinaceous material. Between the cysts, residual renal parenchyma was observed with pronounced fibrosis, areas of microcalcifications, chronic inflammatory infiltrate, regions of fresh hemorrhage, and single or grouped siderophages. Rare glomeruli were present, with some showing partial sclerotic changes. Eosinophilic protein casts were noted in the lumens of the tubules.

Six months after nephrectomy, the patient started with chronic hemodialysis via previous created arterio-venosus fistula. No new episodes of infection or bleeding in the cysts of the remaining kidney have been observed so far.

Table 1. Review of the dynamics of the most important laboratory parameters in the presented patient during hospitalization, five days after nephrectomy, and six months after the surgery when hemodialysis was initiated

Parameter	1st day	3rd day	7th day	5 days after operation	6 months after operation
Hemoglobin (120-180 g/l)	82	90	75	119	89
Erythrocytes (4.2-5.5x10^{12}/l)	3.1	3.3	2.7	4.3	3.4
Leucocytes (4-9 x 10^{9}/l)	8.7	9.5	8.1	6.1	4
CRP (< 6 mg/l)	135	221	128	29	2.3
Creatinine (45-109 µmol/l)	279	319	304	331	576
Urea (2.7-7.8 mmol/l)	12	12.8	11	15	26
Calcium (2.1-2.6 mmol/l)	1.97	1.9	1.9	2.1	2.1
Phosphate (0.8-1.4 mmol/l)	0.84	1.69	1.6	/	1.8
Potassium (3.8-5.5 mmol/l)	4	4.2	3.8	5	4.3
Sodium (137-145mmol/l)	134	135	136	138	144

Discussion

The APKD is a genetically inherited disorder that can lead to significant morbidity, primarily due to a progressive renal cyst formation and associated complications, including haemorrhage, infection and chronic kidney disease [3]. This case highlights a complex clinical scenario in which a 57-year-old female with APKD presented with recurrent urinary infections, dysuria, haematuria and elevated inflammatory markers, ultimately leading to a diagnosis of intracystic haemorrhage and the need for nephrectomy. The patient`s history of recurrent urinary tract infections (UTIs), elevated inflammatory markers and cyst infection, as evidenced by positive urine cultures, is a common complication in APKD [4]. CKD up to the stage IV CKD,

as seen in this case with a serum creatinine of 222 mmol/L, were also frequently observed in individuals with APKD, particularly as the disease progresses

Chapman A, *et al*., have reported that an infected cyst can become resistant to antibiotic treatment due to a thick cyst wall that impairs drug penetration [3]. One of the critical complications observed in APKD is haemorrhage into the cyst, due to increased vascular fragility within the cyst walls. The patient in this case exhibited elevated inflammatory markers, fever, haematuria and anaemia, suggesting an intracystic haemorrhage, as confirmed by CT urography. Intracystic haemorrhage is known to present with sudden onset of pain, hematuria and sometimes fever, reflecting the severe nature of the complication [5]. Sussman *et al*., reports of the presence of hyperdense foci in the cysts on CT scans that did not enhance with contrast, was indicative of a hemorrhagic event [6].

The management of APKD-associated complications often involves conservative measures, including hydration and electrolyte supplementation, as well as antibiotic therapy when infection is suspected [7]. However, as seen in this case, conservative treatment was insufficient, and the patient required surgical intervention. The decision to proceed with unilateral nephrectomy was based on the patient`s worsening kidney function and anaemia. Nephrectomy is considered in patients with end-stage disease, recurrent infections, or severe haemorrhage, and it can be a life-saving procedure [8]. A study by Torres *et al*., [9] demonstrated that the risk of haemorrhage increases with cyst size and underlying hypertension, both common features in APKD patients. A study by Chia-Ter Chao *et al*., [10] reported that the nephrectomy significantly improves quality of life in patients with recurrent cyst complications, particularly those requiring dialysis. Furthermore, a study by Chapman *et al*., [3] highlighted that the laparoscopic nephrectomy offers better postoperative recovery and reduced complications compared to an open surgery in APKD patients.

Comparing this case to previous studies, it is evident that while conservative treatment remains the first line of management, surgical intervention is often necessary when complications arise. Unlike the case reported by P. Duriseti *et al*., [11], where haemorrhagic cysts were managed successfully with supportive care, this patient required a nephrectomy due to a persistent anemia and worsening kidney function. Similarly, studies by Torres *et al*., [9] suggest that while tolvaptan has shown promise in slowing cyst growth, it does not mitigate the risk of hemorrhagic or severe infection, underscoring the importance of individualized treatment strategies.

While nephrectomy remains a critical intervention for severe cases of APKD, emerging therapies aim to slow disease progression and prevent complications such as cyst haemorrhage and infection. One of the most promising pharmacological treatments is tolvaptan, a vasopressin V2 receptor antagonist that has been shown to slow cyst growth and preserve kidney function. Clinical trials, such as the TEMPO 3:4 study, have demonstrated that tolvaptan reduces kidney volume expansion and delays the decline of renal function in APKD patients [3]. However, its role in preventing hemorrhagic complications remains under investigation.

Gene therapy and targeted molecular treatment are also emerging as potential strategies for APKD management. Research into PKD1 and PKD2 gene modulation has shown promise in preclinical studies, with RISPR-based genome editing being explored as a potential approach to correct pathogenic mutations [12]. Additionally, the use of mechanistic target of rapamycin (mTOR) inhibitors, such as sirolimus and everolimus, has been investigated due to their ability to inhibit cyst proliferation and reduce kidney volume [13,14].

In addition to pharmacological interventions regenerative medicine is being explored as a future option for APKD patients. Advances in stem cell therapy and kidney tissue engineering may eventually offer alternatives to nephrectomy and dialysis by promoting kidney regeneration and functional repair [15]. Although these approaches are still in the experimental phases, they hold a great potential for transforming the management of APKD in the future.

Another novel approach involves the use of somatostatin analogs, such as ocreotide and lanreotide, which have been found to reduce cyst growth and slow disease progression in some patients. These therapies work by reducing cyclic AMP levels, which play a crucial role in cyst expansion [16]. Recent studies have reported positive outcomes in patients treated with these analogs, though further research is needed to establish long-term efficacy and safety.

The management of APKD remains challenging due to its progressive nature and the multitude of complications that can arise. The impact of haemorrhagic complication, as seen in this case, underscores the importance of early recognition and intervention. While conservative measures such as hydration and antibiotics are essential, surgical intervention, such as nephrectomy, may be required in severe cases, particularly when patients experience substantial haemorrhage or infection.

Conclusion

This case illustrates the complexities of managing ADPKD, particularly in patients who develop complications such as intracystic hemorrhage, CKD, and infections. The need for an early diagnosis, prompt treatment of infections, and careful monitoring of renal function is critical in preventing further deterioration. In severe cases, nephrectomy remains a viable therapeutic option, although it is typically reserved for advanced disease stages. Further research should focus

on improved pharmacologic therapies to reduce the incidence of hemorrhagic and infectious complications.

Conflict of interest statement. None declared.

References

1. Torres VE, Harris PC, Prison Y. Autosomal dominant polycystic kidney disease. *The Lancet*, 2007; 369(9569): 1287-1301.
2. Spithoven E, Kramer A, Meijer E, *et al*. Renal replacement therapy for autosomal dominant polycystic kidney disease (ADPKD) in Europe: prevalence and survival-an analysis of data from the ERA-EDTA Registry. *Nephrol Dial Transplant* 2014; 29: 15-25.
3. Chapman AB, Devuyst O, Eckardt KU, *et al*. Autosomal dominant polycystic kidney disease (ADPKD): Executive summary from a Kidney Disease: Improving Global Outcomes (KDIGO) Controversies Conference. *Kidney International* 2015; 88(1): 17-27.
4. Alma Idrizi, *et al*. Urinary tract infections in polycystic kidney disease. *Med Arh* 2011; 65(4): 213-215.
5. Otto W, Psomiadis JS, Kirshner B. Management of suspected Renal Cyst Infection with intracystic Hemorrhage in a patient with Autosoman Dominant polycystic Kidney Disease. *Cureus* 2023; 15(5): e39319.
6. Sussman S, *et a*l. Hyperdense renal masses: a CT manifestation of hemorrhagic renal cysts. *Radiology* 1984. https://doi.org/10.1148/radiology.150.1.6689762.
7. Torres VE, Ahn C, Barten TRM, *et al*. KDIGO 2025 clinical practice guideline for the evaluation, management, and treatment of autosomal dominant polycystic kidney disease (ADPKD): executive summary. *Kidney International* 2025; 107(2): 234-254.
8. Dunn MD, Portis AJ, Elbahnasy AM, *et al.* Laparoscopic nephrectomy in patient with end-stage renal disease and autosomal dominant polycystic kidney disease. *American Journal of Kidney Disease* 2020; 35(4): 720-725.
9. Torres VE, *et al*. Tolvaptan in patients with autosomal dominant polycystic kidney disease. *N Engl J Med* 2012; 367: 2407-2418.
10. Chia-Ter Chao, *et al*. Bilateral Nephrectomy Significantly Improves Health-Related Quality of Life in a Hemodialysis Patient with Autosomal Dominant Polycystic Kidney Disease. *American Journal od Kidney Disease* 2013; 1221-1222.
11. Duriseti P, *et al*. Life-Treatening Retroperitoneal Hemorrhage Following Cyst Rupture in Autosomal Dominant Polycystic Kidney Disease (ADPKD): A case Report. *American Journal of Case Reports* 2023; 24: e938889.
12. Nguyen LT. Emerging therapies for autosomal dominant polycystic kidney disease-Current Perspectives. *Journal of Nephrology and Therapeutics* 2024.
13. Shillingford JM, Murcia NS, Larson CH, *et al*. The use of CRISPR/Cas9 PKD1 and PKD2 gene correction: Promising preclinical studies. *I Am Soc Nephrol* 2022; 33(7): 1284-1297.
14. Walz G, Budde K, Mannaa M, *et al*. Everolimus in patients with autosomal dominant polycystic kidney disease. *N Engl J Med* 2010; 363(9): 830-840.
15. Reiterova J, Tesar V. Autosomal Dominant Polycystic Kidney Disease: From Pathophysiology of Cystogenesis to Advances in the Treatment. *International Journal of Molecular Sciences* 2022; 23(6): 3317.
16. Suwabe T, Barrera FJ, Rodriguez-Gutierrez R, *et al*. Somatostatin analog therapy effectiveness on the progression of polycystic kidney and liver disease: A systematic review and meta-analysis of randomized clinical trials. *PLoS One* 2021; 16(9): e0257606.

BANTAO Journal 2023; 22(2): 46-49

BJ
BANTAO Journal

Case report

Anesthesia Considerations for a Better Kidney Function in Patient with Radical Nephrectomy and Inferior Vena Cava Thrombectomy: A Case Report

Marija Cvetkova Mladenovska[1], Aleksandra Gavrilovska Brzanov[1], Sasho Dohchev[2], Aleksandra Mitrevski Ivanovikj[3], Aneta Korunovska[4] and Dijana Jovanova[5]

[1]University Clinic for Traumatology, Orthopedics, Anesthesiology, Resuscitation, Intensive Care and Emergency Center- Skopje, Department of Anesthesiology, Resuscitation and Intensive Care Medicine, [2]University Clinic for Urology, Medical Faculty, University Ss Cyril and Methodius, Skopje, [3]University clinic for surgical diseases " St. Naum of Ohrid", Skopje, [4]General Hospital of Ohrid, [5]University Clinic of Ophthalmology, Medical Faculty, University Ss Cyril and Methodius, Skopje, Republic of North Macedonia

Abstract

Renal cell carcinoma (RCC) is the most common type of kidney cancer, originating from the epithelial cells of the renal tubules. Anesthesia management during surgical procedures to excise malignant tumors that have metastasized into the renal vein or inferior vena cava is exceedingly challenging due to the elevated risk of thrombus emboli displacement, potentially resulting in pulmonary obstructions or cardiac or neurological complications. The stable vital parameter should be also preventing development of acute kidney injury and in addition, the possible deterioration of kidney function on top of the already halved one with the nephrectomy.
We present a case of a 69-year-old male patient admitted to the University Clinic of Urology for scheduled radical nephrectomy due to RCC. An open nephrectomy was conducted under general anesthesia combined with epidural analgesia. During the operation, the patient had a significant hypotension, tachycardia, and a substantial reduction in end-tidal CO_2 levels. Bilateral mydriasis was also observed. Timely administration of anticoagulants and vasoactive drugs resulted in clinical stabilization. Thereafter, we experienced an additional episode of hemorrhage from the a. lienalis, requiring splenectomy as an appropriate therapeutic option. At the end of the surgery, the patient was extubated from mechanical ventilation within the subsequent 30 minutes. The postoperative period was steady, exhibiting optimal hemodynamic and clinical conditions. The patient was discharged seven days post-operation in a good health, with nearly the same kidney function as before the nephrectomy, and without neurological complications. This case highlights the importance of thorough anesthetic preparation, precise hemodynamic monitoring, and synchronized intraoperative treatment following radical nephrectomy with tumor thrombus extending into the inferior vena cava.

Keywords: Anesthesia management, radical nephrectomy, renal cell carcinoma, vena cava thrombus, kidney function

Introduction

Renal cell carcinoma (RCC) is the most prevalent kind of renal cancer, arising from the epithelial cells that are part of the kidney tubules [1]. Carcinoma cells may penetrate in the renal veins, leading to the development of a renal vein tumor thrombus, which may result in its infiltration into the inferior vena cava (IVC) and perhaps extend to the right atrium [2]. In around 4% to 19% of patients with RCCs, tumors infiltrate the IVC [2,3]. It is approximately twice as prevalent in men than in women and typically manifests in the seventh decade of adulthood. Cigarettes are the primary risk factor. Additional significant risk factors are overweight, high blood pressure, and acquired polycystic kidney disease [4]. Surgical resection remains the mainstay of treatment for localized as well as locally advanced disease [1]. Surgery may induce postoperative problems such as surgical access issues, hemorrhage, extensive blood transfusion, coagulopathy, lung embolism, and significant fluid changes [5]. Anesthetic handling for the surgical excision of malignant tumors complicated by thrombus metastasizing into the renal vein or inferior vena cava is highly challenging due to the elevated risk of tumor thrombus movement, potentially leading to embolism in the lungs or cardiovascular failure [5]. In the same line, one should consider also the residual kidney function after the nephrectomy. Certainly, the stable vital parameter should be also preventing deve-

Correspondence to: Aleksandra Gavrilovska Brzanov, University Clinic for Traumatology, Orthopedic Disease, Anesthesiology, Reanimation and Intensive Care Medicine and Emergency Department, 1000 Skopje, R. N. Macedonia; E-mail: gavrilovska.aleksandra@gmail.com

lopment of acute kidney injury and in addition, the possible deterioration of kidney function on top of the already halved one with the nephrectomy.
This case report analyzes our perioperative management and emphasizes the aspects that led to a satisfactory outcome.

Case presentation

A 69-year-old male patient was scheduled for a radical nephrectomy due to radiologically confirmed RCC with extension into the inferior vena cava. His medical history was significant for arterial hypertension and persistent left bundle branch block (LBBB). Long-term pharmacological treatment comprised a beta-adrenergic receptor antagonist, an angiotensin-converting enzyme (ACE) inhibitor, a lipid-lowering agent (statin), and an antiplatelet medication. Upon admission, the patient was hemodynamically stable, had preserved blood pressure and a mildly elevated heart rate, with an age related, slightly reduced kidney function, afebrile. Laboratory analyses revealed leukocytosis, with a white blood cell count modestly above the upper normal range. Abdominal ultrasound showed steatotically changed liver parenchyma. The right kidney was without obstructive changes, and the left kidney was with solid heteroechogeny, and a change that covers almost the entire cortex, requiring further investigations. The computed tomography has shown thickened left basal pleura. Right kidney was with postcontrast imbibition and elimination. A projection of the left splenic-renal region showed a solid hetero-dense change with dimensions of 120x110 mm, with zones of disintegration and calcifications, which most likely originated from the adrenal gland. The left kidney appeared smaller in size, but a clear differentiation could not be made whether the change described has been in close contact with it. Enlarged lymph nodes up to 1 cm have been seen para-aortically. Although radiological interpretation did not reveal any thrombotic material within the inferior vena cava, the attending surgeon retained a heightened suspicion of IVC involvement, which was later corroborated during the operation. The patient was given American Society of Anesthesiologists (ASA) physical status III. Based on the clinical and radiological findings, the patient underwent an open radical nephrectomy.
We evaluated the kidney function through laboratory analyses and glomerular filtration rate preoperatively. Our patient had blood urea nitrogen (BUN) and createnine in referent range preoperative with 3.6 mmol/L and 75 umol/L, respectively, with an eGFR of 89 mL/min/1.73 m^2.
Upon the patient's arrival in the operating room, one 18 G and one 16 G peripheral intravenous catheter were placed to secure venous access prior to anesthetic induction. Monitoring encompassed non-invasive blood pressure (NIBP), electrocardiography (ECG), pulse oximetry, and body temperature. His essential parameters were BP 200/100 mmHg, SpO_2 92%, and the ECG indicated sinus rhythm with a heart rate of 95 beats per minute. An epidural catheter was subsequently inserted at the Th10-Th11 level of the thoracic spine. A test dose of bupivacaine 0.5% was administered. Subsequently, the induction commenced. For induction of anesthesia, the subsequent drugs were delivered consecutively: 1 mg of midazolam, 100 mcg of fentanyl, 40 mg of lidocaine, 100 mg of propofol, and 50 mg of rocuronium bromide. Tracheal intubation was successfully performed utilizing an 8.0 endotracheal tube and a conventional laryngoscope. The tidal volume was sustained at 6-8 ml/kg, the respiratory rate was 12 breaths per minute, and PEEP was set at 5 in the pressure-controlled volume guarantee ventilation mode. $EtCO_2$ was sustained within the range of 35 to 45 mmHg with respiratory rate adjustment. To sustain anesthesia, 1%-2% sevoflurane was continuously administered via inhalation at a MAC of 0.6-1, propofol was infused continuously at a rate of 30-40 ml/h, and fentanyl was administered intravenously in an intermittent manner. Bupivacaine 0.25% was administered intermittently via the epidural catheter in a dose of 2mg hourly. An arterial blood line was inserted into the right brachial artery post-induction to measure invasive blood pressure (IBP). Central venous catheterization in the internal jugular vein was executed to enable volume management, delivery of vasoactive medications, and assessment of central venous pressure (CVP). During the initial two hours, the patient exhibited hemodynamic stability, with blood pressure ranging from 110/60 to 120/70 mmHg and a heart rate of 60 to 80 beats per minute and CVP was maintained at 10 mmHg.
During the operation, roughly two hours after its commencement, the patient suffered from a sudden and significant haemorrhage, resulting in a rapid decline in blood pressure to 60/40 mmHg, and a notable decrease in end-tidal CO_2 ($EtCO_2$) to 12 mmHg, an elevation in heart rate to 140 beats per minute, and an increase in CVP to 18 mmHg with a consequent bilateral mydriasis. The initial therapy comprised with an intravenous delivery of 5000 IU of heparin, bolus vasopressors (phenylephrine 500 mcg and adrenaline 100 mcg), succeeded by a continuous adrenaline infusion at a rate of 0.05 mcg/kg/hour. The mydriasis subsided within 30 seconds. Blood pressure progressively enhances, attaining 80/50 mmHg within 10 minutes and subsequently 90/60 mmHg. The EtCO2 reading incrementally rose to 25, subsequently to 28, and ultimately reached 31 mmHg. Hemorrhage was managed using mechanical means. One unit of packed red blood cells and one unit of fresh frozen plasma were delivered. Thirty minutes post-initial stabilization, rebleeding ensued, with the splenic artery identified as the source. An urgent splenectomy was performed.

Arterial blood gas was obtained, and measurements revealed pH 7.31, pCO_2 35.7 mmHg, pO_2 131 mmHg, hemoglobin 9.5 g/dL, oxygen saturation 99%, and lactate 2.2 mmol/L. During the procedure, fluid resuscitation was sustained using crystalloids and colloids at a rate of 15 ml/kg/hour. Because of the hemodynamic instability and lack of urine production at the conclusion of the procedure, diuresis was pharmacologically induced with an intravenous furosemide at a dosage of 10 mg.
At the end of surgery, neuromuscular blockage was antagonized using neostigmine and atropine. Twenty minutes later, the patient was effectively weaned from mechanical ventilation and extubated. He was relocated to the post-anesthesia care unit, where he was monitored for one hour. Given that his vital signs and neurological condition were stable, he was transported to the urology department.
The postoperative laboratory findings from the first to the seventh postoperative day showed preserved renal function with Hgb from 85 to 100 g/L, BUN from 2.1 to 3 mmol/L and creatinine 71 -75 umol/L. Interestingly, his eGFR was around the same as previously 89 mL/min/1.73 m^2. Postoperative trends are presented in figure 1. The postoperative recovery was unremarkable, and the patient was discharged on the seventh day post-surgery.

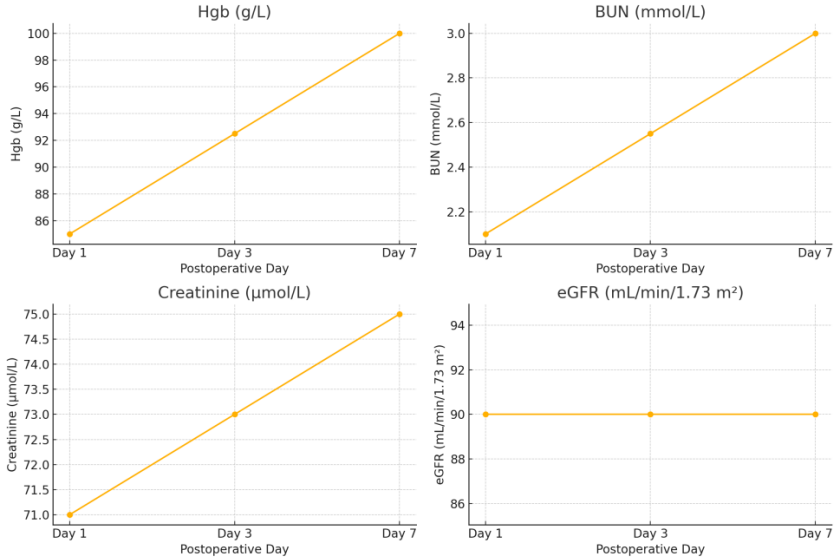

Fig. 1. Trend of Postoperative Hgb, BUN, Creatinine, and eGFR Levels Indicating Preserved Renal Function

Discussion

Regardless of advancements in radiation, chemotherapy, and immunotherapy, surgical excision is still the mainstay approach for RCC, including tumor thrombus [6]. Performing a radical nephrectomy involving the incision of the inferior vena cava to excise invasive tumors or thrombus has a 1-month death rate of 1-10% and a serious complications risk of 18-47% [7]. The perioperative assessment and anesthetic management during radical nephrectomy with inferior vena cava thrombectomy can provide significant challenges. Consequently, it is essential for the team of specialists to recognize the hemodynamic alterations that transpire during caval manipulation. The primary elements of intraoperative monitoring encompass fluid management, the preservation of steady hemodynamic parameters, and the prompt management of potential embolism [8]. We did not use transthoracic echocardiography (TTE), but we vigilantly followed invasive blood pressure, clinical signs, and $EtCO_2$.
$EtCO_2$ encompasses all facets of respiration and circulation, consequently offering a comprehensive evaluation of pulmonary and cardiovascular dynamics. Under stable respiratory conditions, $EtCO_2$ serves as a metric for assessing the cardiac output and pulmonary blood flow.
In general anesthesia patients, it could indicate perioperative poor output of the heart, organ inadequate perfusion i.e. kidneys, and consequent postoperative organ failure [9]. Perioperative pulmonary embolism (PE) affects nearly six percent of patients with IVC tumor thrombus, with death rates ranging from around 70%. PE often occurs during renal and inferior vena cava dissection and clamps [10]. In our case, considering all the details, PE was one of the possible causes of hemodynamic and respiratory abnormalities. Next, in both the Trendelenburg and kidney positions, the surgical field is elevated above the heart, establishing a negative pressure gradient that exists between the area of surgery and the heart. Air embolism may arise if the venous plexus is compromised when the patient is in a head-down posture during radical prostatectomy or cystoprostatectomy, or if the vena cava is breached during the radical nephrectomy. A large air embolism may result in a reduction of end-tidal carbon dioxide or an elevation of end-tidal nitrogen. Physical manifes-

tations indicative of air embolism encompass abrupt hypotension, hypoxemia, arrhythmia, and the detection of a mill-wheel murmur [11]. The decrease in $EtCO_2$ could be due to the loss of lung perfusion, and dilated pupils were most probably secondary to the cerebral hypoxia.

Furthermore, left radical nephrectomy was noted as the second most prevalent reason for inadvertent spleen removal in surgical abdominal procedures. Intraoperative documentation commonly indicates that nonspecific "spleno-renal adhesions" result in avulsion of the splenic capsule, predominantly at the lower pole of the spleen. Another frequently cited cause of splenic injury is the trauma from a hand retractor, and occasionally, unintentional laceration of the splenic capsule [12]. The reduction in the renal mass usually results in a diminished renal function. The excision of fifty percent of the renal mass with a radical nephrectomy promptly diminishes renal function to approximately half of its pre-nephrectomy level. Nevertheless, within a brief period, the surviving contralateral kidney starts to compensate for the diminished renal function [13], certainly, in cases without ensued acute kidney injury. In our case despite the intraoperative haemodynamic instability and the hypoperfusion in a short period of time, the patient had a satisfactory outcome with a preserved renal function. Following the patient one year after the operation he is with BUN and creatinine in normal ranges, good protein status, a satisfactory dieresis and eGFR in the normal age adjusted range.

Notwithstanding the intricacies of the intraoperative process, the patient was adeptly handled, achieving effective bleeding control and a successful completion of the treatment, which included splenectomy. We assert that the intraoperative application of transesophageal echocardiography (TEE) would have been beneficial for prompt diagnosis and real-time hemodynamic evaluation. Nonetheless, meticulous analysis of clinical indicators, invasive blood pressure monitoring, and $EtCO_2$ changes facilitated swift decision-making and a positive conclusion.

Conclusion

A nephrectomy including thrombus in the inferior vena cava necessitates meticulous planning and specialized anesthetic management. Effective management of hemorrhage and vascular manipulation during radical nephrectomy necessitates the implementation of accurate hemodynamic monitoring thus preserving also the kidney function. A multidisciplinary team approach is essential with anesthesia and surgery teams coordinated as to provide best patient outcomes.

Conflict of interest statement. None declared.

References

1. Chen S, Lu L, Zheng X, Lin Y, Bao L, Zhang B, Yang Z. Case report: Anesthetic management for removal of tumor thrombus in the inferior vena cava and pulmonary artery in renal cell carcinoma. *Front Oncol* 2024; 14: 1372625.
2. Stanoevska M, Gavrilovska Brzanov A, *et al*. Managing dual pathologies nephrectomy for renal cell carcinoma in a patient with severe tricuspid valve regurgitation. *MJA* 2025; 9(1): 107-112.
3. Rehman ZU, Ather MH, Aziz W. Surgical Interventions for Renal Cell Carcinoma with Thrombus Extending into the Inferior Vena Cava: A Multidisciplinary Approach. *Ann Vasc Dis* 2019; 12(1): 55-59.
4. Chapman E, Pichel A. Anaesthesia for nephrectomy. BJA Education, 2016; 16(3): 98-101.
5. Chen K, Wang J, Dai J, *et al*. Anesthetic management of radical nephrectomy in patients with renal cell carcinoma involving renal vein or inferior vena cava. *Tumori* 2019; 105(5): 411-416.
6. Ashraf H, Rehman R, Hussain S, *et al*. Complications of transperitoneal radical nephrectomy: a single-center experience. *Annals* 2015; 21 (3): 144-148.
7. Vu Ton Ngoc Phan, Phat Thanh Tran, Dao Thi Ngoc Nguyen. Anesthetic Management of Renal Tumor with Level 3 Inferior Vena Cava Extension at a University Hospital in Vietnam: A Case Report. *Case Rep Oncol* 2025; 18 (1): 120-129.
8. Garg H, Kaushik D, Hui D, *et al*. Haemodynamic changes during radical nephrectomy with inferior vena cava thrombectomy: A pilot study. *BJUI Compass* 2022; 3(5): 327-330.
9. Dong L, Takeda C, Kamitani T, *et al*. Association between intraoperative end-tidal carbon dioxide and postoperative organ dysfunction in major abdominal surgery: A cohort study. *PLoS One* 2023; 18(3): e0268362.
10. Wang Yaozhu MMa, Wang Xu PhDb, Chang Yuan PhDb. Radical nephrectomy combined with removal of tumor thrombus from inferior vena cava under real-time monitoring with transesophageal echocardiography: A case report. *Medicine* 2020; 99(11): e19392.
11. Monk TG. Complications of radical urologic surgery. In: Atlee JL, editor. *Complications in Anesthesia*. 2nd ed. Philadelphia: W.B. Saunders; 2007; 846–849.
12. Carmignani G, Traverso P, Corbu C. (Incidental Splenectomy during Left Radical Nephrectomy: Reasons and Ways to Avoid It. *Urologia Internationalis* 2001; 67(3): 195-198.
13. Chapman D, Moore R, Klarenbach S, Braam B. Residual renal function after partial or radical nephrectomy for renal cell carcinoma. *Can Urol Assoc* J 2010; 4(5): 337-343.

BANTAO Journal 2023; 22(2): 50-53

BJ
BANTAO Journal

Case report

A Case of Spontaneous Bilateral Renal Artery Dissection

Merve Araslan[1], Sinem Girgin[2], Ferdi Cay[3], Bora Peynircioglu[3], Mustafa Arici[2]

[1]Hacettepe University, Department of Infectious Diseases, [2]Hacettepe University, Department of Internal Medicine, Division of Nephrology, [3]Hacettepe University, Department of Interventional Radiology, Ankara, Türkiye

Abstract

Introduction. Spontaneous renal artery dissection (SRAD) is defined as dissection of the renal artery without an underlying vascular disease, intervention or trauma. Approximately 200 cases of SRAD have been reported in the literature and its bilateral involvement is much rarer. It is a rare condition and its incidence and clinical findings are not well known. Most common finding is hypertension, and most common symptoms are sudden onset waist or flank pain and hematuria. It is difficult to diagnose as it can often be confused with renal colic or pyelonephritis. Patients who do not undergo computed tomography (CT) are often treated as urolithiasis.

Case presentation. We would like to present here a 38-year old male patient who has bilateral SRAD and has difficulties in diagnosis and treatment.

Conclusion. CT is important in the diagnosis of renal infarction and dissection in cases with flank pain of unknown origin, and CT evaluation should always be considered in cases without concomitant diseases. Anticoagulant and antihypertensive therapy, endovascular procedures, open vascular surgery and nephrectomy are effective treatment options. Although there is no consensus on the choice of treatment options. The diagnostic dilemma and uncertainty of the treatment management in such cases can only be resolved by presenting more case experiences in the literature.

Keywords: Renal artery dissection, renal infarction, renovascular disease, flank pain, hematuria

Introduction

Spontaneous renal artery dissection (SRAD) is defined as dissection of the renal artery without an underlying vascular disease, intervention or trauma. It is a rare condition and its incidence and clinical findings are not well known [1,2]. SRAD was first described in the literature in 1944 [3]. It constitutes 1-2 % of arterial dissections [4,5].

Most common finding is hypertension, and most common symptoms are sudden onset waist or flank pain and hematuria. It is difficult to diagnose as it can often be confused with renal colic or pyelonephritis. It has three different presentations. These are subacute state without serious progression, renal infarction state due to acute occlusion, and chronic state with renovascular hypertension. It is difficult to detect dissection with conventional methods such as ultrasonography or doppler ultrasonography. Patients who do not undergo computed tomography (CT) are often treated as urolithiasis [3,6]. CT, intravenous pyelography, or magnetic resonance imaging may be helpful in diagnosis; but the gold standard diagnostic method is angiography [1].

Anticoagulant and antihypertensive therapy, endovascular procedures, open vascular surgery and nephrectomy are effective treatment options. Although there is no consensus on the choice of treatment options, the general opinion is that an interventional procedure should be planned in cases of failure to control blood pressure with medical treatment or progressive loss of renal function [7].

We here would like to present a case who has bilateral involvement (which is rare) and has difficulties in diagnosis and treatment.

Case Presentation

A 38-year-old male patient who had no previous medical history went to a local hospital's emergency department following a sudden onset right flank pain and nausea. In physical examination he was nonfebrile and normotensive. Except for lactate dehydrogenase (LDH) elevation, complete blood count, kidney and liver function tests and complete urinalysis with microscopy were normal.

A contrast enhanced computed tomography (CT) scan showed right renal parenchymal multifocal infarction and acute occlusion underlining dissection of segmen-

Correspondence to: Sinem Girgin, Hacettepe University, Department of Nephrology, Ankara, Türkiye Turkey; E-mail: snmgirgn@gmail.com

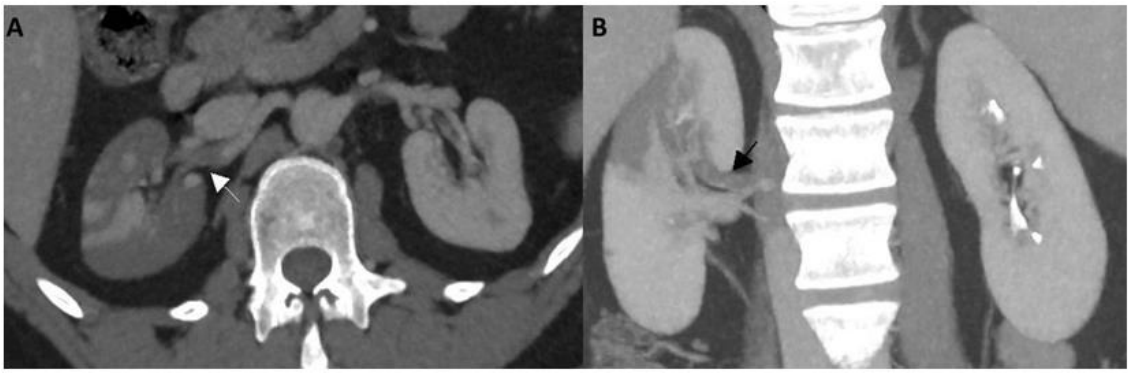

Fig. 1. Axial (A) and coronal (B) abdomen BT images show wedged shaped hypoattenuation of renal parenchyma due to ischemia and acute occlusion underlining dissection of segmental renal artery (Arrows in A and in B)

tal branch of renal artery that supply superolateral part of right kidney (Figure 1).

Table 1. Patient's first biochemical and hematologic tests

Patient's first biochemical and hematologic tests	Results	Referance range
White blood cell count	13500/mm³	4000-10000
Serum creatinine	1.34 mg/dL	0.75-1.35
Blood urea nitrogen	30 mg/dL	6-24
Lactate dehydrogenase	1775 U/L	105-233
Urine nitrite	Negative	Negative
Urine protein	2+	Negative
Urine erythrocyte	1	0-3
Urine leukocyte	1	0-5
Antithrombin III activity	93.4 %	80-120
Protein C activity	63.8 %	70-140
Protein S activity	110.1 %	60-130
C3 complement	125 mg/dL	75-135
C4 complement	45.7 mg/dL	12-72
Fibrinogen	859 mg/dL	170-420

He was referred to a tertiary center and he was consulted to hematology department in terms of conditions that may predispose to thrombosis. Antithrombin 3, protein S antigen, C3, C4 levels were normal. Protein C activity was slightly low (63,8 %, N: 70-140 %), fibrinojen was elevated (859 mg/dl, N: 170-420 mg/dl). In echocardiogram his ejection fraction was 65 % and there was no intracardiac thrombosis. Oral vitamin K antagonist therapy was started to the patient and he was discharged. He was asymptomatic and monthly follow-ups continued.

6 months later he had left flank pain that woke him up at night. When he admitted to the hospital, his blood pressure was 147/86 mm Hg, heart rate was 110/min, respiratory rate was 22/min and he was afebrile. His laboratory values were white blood cell 13500/mm³, serum creatinine 1.34 mg/dl, blood urea nitrogen 30 mg/dl, LDH 1775 U/L. His liver functions were normal and urinalysis with microscopy showed nitrite negative, 2+ protein, 1 erythrocyte and 1 leukocyte (Table 1). He was consulted to infectious diseases and infective endocarditis was suspected. He was started empirical ceftriaxone 1x2 gr/day treatment. In his transesophageal echocardiogram there was no intracardiac vegetation or thrombosis. There was no microorganism in his blood and urine cultures.

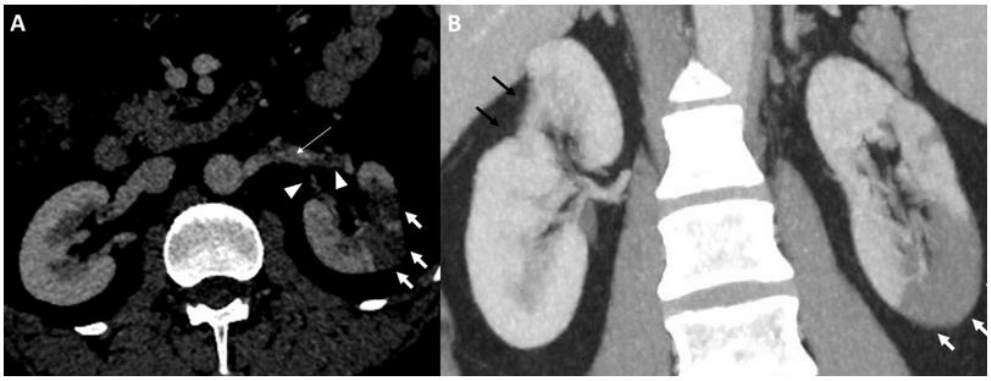

Fig. 2. Axial (A) and coronal (B) abdomen BT images show wedged shaped hypoattenuation of renal parenchyma due to ischemia (thick white arrows in A and B), left renal artery dissection with intimal flap (thin arrow in A) and thrombosis of segmental branches (arrowheads in A). Also, note that there is right parenchymal scarring (black arrows in B) due to previous episode

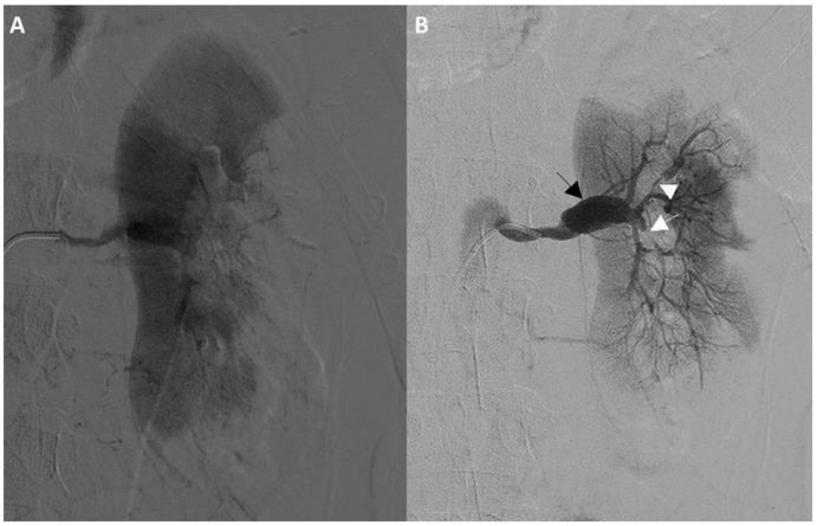

Fig. 3. A) Renal DSA image showing contrast filling defect in peripheral inferolateral part of the left kidney due to ischemia. B) Renal DSA image showing fusiform dilatation of false lumen (black arrow) due to known renal artery dissection, occlusion of segmental branch (white arrow), involvement of interlobar artery (arrowhead)

The patient underwent abdomen CT scan that showed wedged shaped renal parenchymal ischemia and left renal artery dissection and thrombosis of segmental renal artery branches which could be related to the underlying dissection (Figure 2). Ten days after the CT scan, the patient underwent renal digital substraction angiography (DSA) to better delineate renal vasculature. Renal DSA showed parenchymal filing defect due to ischemia, fusiform dilatation of distal renal artery and its segmental branches, and occlusion of inferolateral segmental branch after fusiform dilatation (Figure 3). No interventional procedure was recommended to the patient.

He was consulted to rheumatology department for etiological evaluation and his rheumatological markers were all negative (Table 2). Cranial CT showed no intracranial aneurysm. He was consulted to hematology department for anticoagulant therapy. His oral vitamin K antagonist therapy was switched to novel oral anticoagulants for being more efficient for intraabdominal thrombosis.

Table 2. Patient's rheumatologic and hematologic tests

Rheumatologic and hematologic tests	Results	Referance range
Antithrombin III activity	83.3 %	80-120
Protein C activity	93.4 %	70-140
Protein S activity	103.4 %	60-130
LA verification	33.4 min	30-38
ANA (anti-nuclear antibody)	Negative	Negative
Anti dsDNA	Negative	Negative
ANCA (IFA)	Negative	Negative
ANCA profile (elisa)	Negative	Negative
C3 complement	115 mg/dL	75-135
C4 complement	35.4 mg/dL	12-72
Anti cardiolipine Ig M, Ig G	Negative	Negative
Beta-2 glycoprotein-1 Ig M, IgG	Negative	Negative
Homocysteine	6.0 µmol/L	5-15
PAI-I 4G/5G mutation	Heterozygous	Negative
MTHFR677C mutation	Heterozygous	Negative

As comprehensive investigations for etiology were inconclusive, the patient was considered to have spontaneous bilateral renal artery dissection. His blood pressure was controlled with ramipril 2,5 mg/day. He is currently under regular follow-up, his blood pressure is normal, his renal functions are stable, and no new renal artery embolism has developed in the last 2 years.

Discussion

This patient with renal infarction due to renal artery dissection had no underlying comorbid conditions and had bilateral involvement. As spontaneous renal artery dissection related renal infarction is a rare entity, it obviously created some difficulty in the diagnosis and management. Without a prompt diagnosis and an appropriate follow-up and anticoagulation strategy, he may have some adverse consequences.

There are many causes of renal infarction. The most common cause is cardiogenic thromboembolism. Atrial fibrillation, cardiomyopathy, valvular heart diseases and infective endocarditis are some of the underlying causes [8]. Rare underlying causes are trauma, angiographic procedures, thrombophilic diseases and hematological diseases [9].

In renal artery dissection, which is one of the rare conditions that may lead to renal infarction, fibromuscular dysplasia (FMD), malignant hypertension, severe atherosclerosis, Marfan Syndrome, Ehler Danlos Syndrome, heavy physical activity and cocaine use may be the underlying causes [2,7,10].

Three mechanisms are thought to be effective in the pathogenesis of renal artery dissection. These are shear stress, vaso vasorum rupture and segmental arteriolar mediolysis. Connective tissue diseases, heavy physical activity, trauma, cocaine use and uncontrolled hypertension cause dissection with shear stress. FMD and

mid-vessel vasculitis lead to dissection by causing vasa vasorum rupture and intramural hematoma [11].
In some cases, no etiological cause could be found and these cases were defined as SRAD. Although SRAD is a rare cause of renal infarction, it was shown that 21 (4,79%) of 438 patients with renal infarction had SRAD in the study by Oh *et al*. [8]. In the case series by Yoon *et al*., of 35 patients with renal infarction, SRAD was detected in 6 patients (17,1 %). SRAD was the second most common cause of renal infarction in these series. It has been suggested that this incidence is high because high spatial resolution of current multidetector CT (MDCT) was used in these case series. Therefore, these results may more accurately reflect the incidence of SRAD [5].
More than 200 cases of SRAD have been reported in the literature, one quarter of which are presented in autopsies [12]. It is more common in men than women, and prevalence ratios between 4:1 and 10:1 were reported in the literature. It is mostly seen in the 4th and 6th decades of life [13,14]. Bilateral involvement has been seen in 10-15 % of SRAD cases [7].
The underlying mechanism in SRAD cases is unknown. One hypothesis is that physical exercise causes tension in the arterial wall in these cases, and the other hypothesis is that SRAD cases are a clinical variant of FMD or atherosclerosis [15]. However, in the 6-patient SRAD case series of Renaud et al. no cardiovascular risk factors suggestive of arterial dysplasia or atherosclerosis were found.
The clinical presentation of our case is mainly consistent with previous cases. SRAD usually presents in fit and 30- or 40-year-old males with an abdominal, flank or low back pain [10]. Hypertension is seen in almost all patients with SRAD [1]. Our case was observed to be hypertensive at the time of admission. It has been determined that the incidence of new-onset hypertension in patients with SRAD is higher than in patients with embolism-related renal infarction [5]. Blood tests often show a raised white cell count and renal functions may deteriorate acutely with an elevation of lactate dehydrogenase. Urinalysis sometimes reveals microscopic hematuria, but in our case urinalysis was normal.
There are many options for treatment, from conservative treatment to endovascular and surgical intervenetions. Although there is no consensus on treatment, endo\vascular revascularization is often recommended in cases of hypertension that cannot be controlled with medical treatment or progressive renal dysfunction [7]. Antihypertensive treatment and anticoagulant treatment are medical treatment options to prevent further thrombus formation after endothelial damage. Most of the experience published so far has been with vitamin K antagonists. The optimal duration of anticoagulation is unclear and there is a lack of data on the use of the oral anticoagulants [10].

Conclusion

In conclusion, CT is important in the diagnosis of renal infarction and dissection in cases with flank pain of unknown origin, and CT evaluation should always be considered in cases without concomitant diseases. The diagnostic dilemma and uncertainty of the treatment management in such cases can only be resolved by presenting more case experiences in the literature.

Conflict of interest statement. None declared.

References

1. Kanofsky JA, Lepor H. Spontaneous renal artery dissection. *Rev Urol* 2007; 9(3): 156-160.
2. Pellerin O, Garcon P, Beyssen B, *et al*. Spontaneous renal artery dissection: long-term outcomes after endovascular stent placement. *J Vasc Interv Radiol* 2009; 20(8): 1024-1030.
3. Rumpus HC. A case of renal hypertension. *Trans Am Assoc Genitourin Surg* 1945; 37: 135-140.
4. Antopolsky M, Simanovsky N, Stalnikowicz R, *et al*. Renal infarction in the ED: 10-year experience and review of the literature. *Am J Emerg Med* 2012; 30: 1055-1060.
5. Yoon K, Song SY, Lee CH, *et al*. Spontaneous renal artery dissection as a cause of acute renal infarction: clinical and MDCT findings. *J Korean Med Sci* 2017; 32: 605-612.
6. Peynircioglu B, Piskinkaya S, Ozer C, *et al*. Isolated spontaneous renal artery dissection: diagnosis and endovascular management. *Diagn Interv Radiol* 2011; 17: 101-104.
7. Lacombe M. Isolated spontaneous dissec_tion of the renal artery. *J Vasc Surg* 2001; 33: 385-391.
8. Oh YK, Yang CW, Kim YL, *et al*. Clinical characteristics and outcomes of renal infarction. *Am J Kidney Dis* 2016; 67: 243-250.
9. Bourgault M, Grimbert P, Verret C, *et al*. Acute renal infarction: a case series. *Clin J Am Soc Nephrol* 2013; 8: 392-398.
10. Jha A, Afari M, Koulouridis I, *et al*. Isolated Renal Artery Dissection: A Systematic Review of Case Reports. *Cureus* 2020; 12(2): e6960.
11. Gewertz BL, Stanley JC, Fry WJ. Renal artery dissections. *Arch Surg* 1977; 112: 409-414.
12. Seo Y, *et al*. Spontaneous renal artery dissection resulting in renal infarction: a case report and review of the literature. *Intern Med* 2019; 2530-18.
13. Ng C, Gitman M. Isolated spontaneous renal artery dissection. *Med Forum* 2009; 11: 60-61.
14. Renaud S, Leray-Moragues H, Chenine L, *et al*. Spontaneous renal artery dissection with renal infarction. *Clin Kidney J* 2012; 5: 261-264.
15. Thomas MC, Walker RJ, Packer S. Running repairs: renal artery dissection following extreme exertion. *Nephrol Dial Transplant* 1999; 14: 1258-1259.