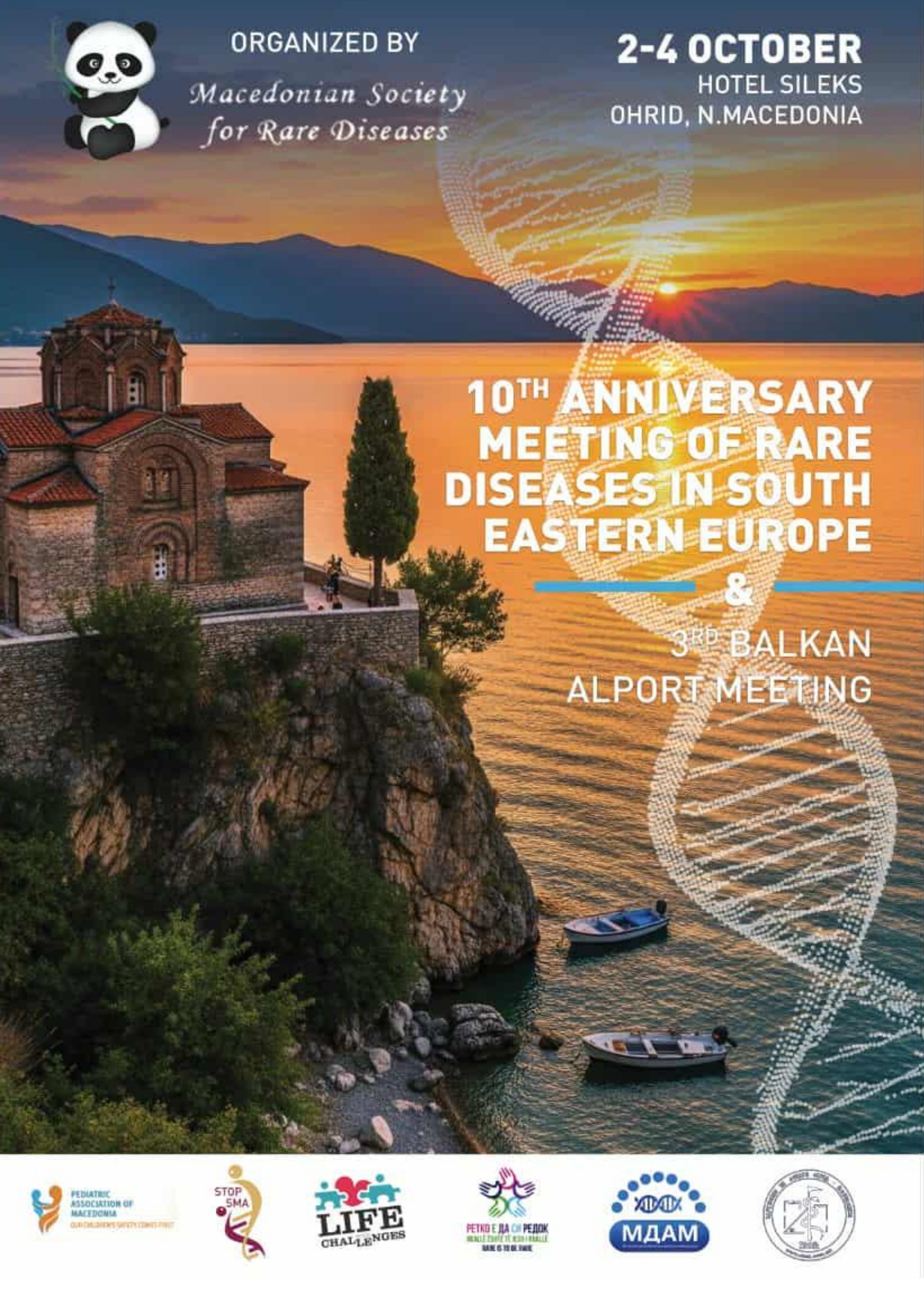
ORGANIZED BY
Macedonian Society for Rare Diseases
2-4 OCTOBER
HOTEL SILEKS
OHRID, N.MACEDONIA
10TH ANNIVERSARY MEETING OF RARE DISEASES IN SOUTH EASTERN EUROPE
&
3RD BALKAN ALPORT MEETING
PEDIATRIC ASSOCIATION OF MACEDONIA
STOP SMA
LIFE CHALLENGES
РЕТКО Е ДА СИ РЕДОК
МДАМ

Macedonian Society
for Rare Diseases

ABSTRACT BOOK

10th Anniversary Meeting of Rare Diseases in South Eastern Europe
& 3rd Balkan Alport Meeting

October 02-04, 2025
Hotel "Sileks"
Ohrid, North Macedonia

TABLE OF CONTENTS

Organizers.....4

Sponsors.....4

Scientific Committee.....5

Organizing Committee.....5

Welcome Message.....6

Scientific Program.....7

Invited Speakers - CVs and Abstracts.....13

Oral Presentations.....82

ORGANIZERS

Macedonian Society for Rare Diseases

PEDIATRIC ASSOCIATION OF MACEDONIA
OUR CHILDREN'S SAFETY COMES FIRST

STOP SMA

РЕТКО Е ДА СИ РЕДОК
RRALLË ËSHTË TË JESH I RRALLË
RARE IS TO BE RARE

LIFE with CHALLENGES
Life is a puzzle, collect it.

МДАМ
МУСКУЛНА ДИСТРОФИЈА АСОЦИЈАЦИЈА МАКЕДОНИЈА

SPONSORS

EXCEED ORPHAN

BIOMARIN

lek
a Sandoz company

Takeda

GENESIS pharma

novo nordisk®

Amicus
a Swixx BioPharma company

MEDIS

Meeting Director

Zoran Gucev (Skopje)

Scientific Committee:

Zoran Gucev

Danko Milosevic

Velibor Tasic

Tatjana Milenkovic

Mirjana Samardzic

Aleksandra Janchevska

Urh Groshelj

Violeta Anastasovska

Nora Abazi Emini

Organising Committee:

Zoran Gucev

Velibor Tasic

Aleksandra Janchevska

Gordana Loleska

Ivan Akimovski

Leo Spaseski

Georgi Stavreski

Ilina Treneska

Teodora Strezoska

WELCOME MESSAGE

Dear colleagues, dear friends,

It is my great honor and pleasure to welcome you to the 10th Anniversary Meeting of Rare Diseases in Southeastern Europe, here in Ohrid, from 2nd to 4th October 2025. This meeting marks not only a decade of scientific exchange, collaboration, and progress in the field of rare diseases, but also the building of a strong community dedicated to patients and families who inspire our work every day.

Over the past ten years, this platform has grown into a unique regional initiative, bringing together clinicians, researchers, geneticists, patient advocates, and policy makers. Together, we have fostered dialogue, strengthened networks, and advanced knowledge—making Southeastern Europe an active contributor to the global rare disease movement.

We are especially proud to host this anniversary in Ohrid, a city of remarkable beauty and history. Known as the "Jerusalem of the Balkans," Ohrid is a UNESCO World Heritage site, famous for its ancient churches, monasteries, and the crystal-clear waters of Lake Ohrid—one of the oldest lakes in the world. We hope you will take the time not only to engage in the rich scientific program, but also to experience the cultural heritage and natural wonders that make this city so unique.

Let this meeting be an opportunity to reflect on our achievements, to exchange new ideas, and to inspire one another for the future of rare disease care and research. May these days in Ohrid strengthen our professional ties and create lasting friendships.

I warmly welcome you and wish us all a fruitful and memorable meeting.

Sincerely yours,

Prof. Zoran Gucev

President of Macedonian Society for Rare Diseases (MSRD)



EAP - Pediatric Section of U.E.M.S

Macedonian Society for Rare Diseases

MSRD 2025

MEETING PROGRAMME

2-4 October 2025



10th Anniversary Meeting of Rare Diseases in South Eastern Europe

& 3rd Balkan Alport Meeting

Thursday, 2 October 2025 - MEETING PROGRAMME

10:30 - 11:00	Press Conference
11:00 - 11:30	Welcome and Opening
	Her excellency the President of the Republic of North Macedonia **Prof. Dr. Gordana Siljanovska-Davkova**
	Minister of Health, North Macedonia **Prof. Dr. Azir Aliu**
	Mayor of Ohrid **Dr. Kiril Pecakov**
	President of the National Committee for Rare Diseases, North Macedonia **Prof. Dr. Zlate Stojanovski**
	Director of the University Children's Hospital **Dr. Rexhep Mehmeti**
11:30 - 12:00	Keynote Lecture
	History and Mistery of Laron Syndrome (Zoom) **Zvi Laron, Petah Tikva, Israel**
12:05 - 14:15	Session I Moderators: Zoran Gucev, Velibor Tasic
12:05 - 12:25	New Developments in Hepatitic Glycogen Storage Disorders **Rene Santer, Hamburg, Germany**
12:25 - 12:45	Genetics and Rare Diseases **Zoran Gucev, Skopje, North Macedonia**
12:45 - 13:05	Diagnosis and Treatment of Inherited Bone Diseases **Nikola Ilic, Belgrade, Serbia**
13:05 - 13:25	Gain-of-function Variants in CLCN7 cause hypopigmentation and lysosomal storage disease **Rene Santer, Hamburg, Germany**
13:25 - 13:45	Diagnostic Pathways of Neuroprogressive Disease – Insights from CLN2 Patients **Ruzhica Kravljanac, Belgrade, Serbia**
13:45 - 14:05	Achondroplasia - Our Experiences and Perspectives **Aleksandra Janchevska, Skopje, North Macedonia**
14:05 - 14:15	Discussion
14:15 - 14:45	Lunch
14:45 - 17:45	Satellite Meeting Third Balkan Alport Meeting
14:45 - 15:00	Introductory Remarks **Velibor Tasic and Gordana Loleska, Skopje/Ohrid, North Macedonia**

15:00 - 15:20	Caring Together for Children with Chronic Kidney Disease **Yaacov Frishberg, Jerusalem, Israel**
15:20 - 15:35	Kidney Cysts and Alport Syndrome **Nora Abazi-Emini, Skopje, North Macedonia**
15:35 - 16:00	New Treatment Options in Alport Syndrome **Detlef Bockenhauer, Leuven, Belgium**
16:00 - 16:20	Genetic Counseling Issues in Alport Syndrome **Todor Arsov, Shtip, North Macedonia**
16:20 - 16:30	Discussion
16:30 - 16:45	Coffee Break
16:45 - 17:00	Dialysis Treatment - Modalities and Updates **Nikolina Smokovska, Skopje, North Macedonia**
17:00 - 17:15	Kidney Transplantation in Alport Syndrome Patients - Clinical Challenges and Experience **Aleksandra Gavrilovska Brzanov, Skopje, North Macedonia**
17:15 - 17:30	Report from the Beijing Alport Meeting **Susan Gear, Oxford, United Kingdom**
17:30 - 17:45	Ask the Expert
17:45	Closing remarks
17:45 - 18:45	Symposium
17:45 - 18:05	Primary Hyperoxaluria Type 1 – Early Onset Presentation **Nora Abazi-Emini, Skopje, North Macedonia**
18:05 - 18:30	Novel Therapeutic Approaches for Primary Hyperoxaluria **Yaacov Frishberg, Jerusalem, Israel**
18:30 - 18:45	Report on the Survey of Diagnostic and Treatment Challenges in SEE **Velibor Tasic, Skopje, North Macedonia**
	Discussion

20:30	Get Together Dinner, Hotel Silex Ohrid

EAP - Pediatric Section of U.E.M.S

Macedonian Society for Rare Diseases

MSRD 2025

MEETING PROGRAMME

2-4 October 2025



10th Anniversary Meeting of Rare Diseases in South Eastern Europe

& 3rd Balkan Alport Meeting

Friday, 3 October 2025 - MEETING PROGRAMME

08:30 - 10:40	**Session II (Hall A)** **Moderators: Zoran Gucev, Tatjana Milenkovic**
08:30 - 08:50	Novel Rare Forms of Differences of Sex Development **Tulay Guran, Istanbul, Turkey**
08:50 - 09:10	Founder Mutations and Rare Genetic Disorders in Roma Populations of Central and Eastern Europe **Martin Magner, Prague, Czech Republic**
09:10 - 09:30	Diagnostic Challenges in Distal Renal Tubular Acidosis **Detlef Bockenhauer, Leuven, Belgium**
09:30 - 09:50	Management of Distal Renal Tubular Acidosis **Danko Milosevic, Zagreb, Croatia**
09:50 - 10:10	Early Onset of Severe Obesity: What Could It Be? **Tatjana Milenkovic, Belgrade, Serbia**
10:10 - 10:30	Advances in Treatment Familial Hypercholsterolemia **Ramush Bejiqi, Prishtina, Kosovo**
10:30 - 10:40	Discussion
10:40 - 11:15	**Mini Symposium** **Moderators: Velibor Tasic, Nora Abazi Emini**
	Meet the Expert: X-linked hypophosphatemic rickets **Expert: Detlef Bockenhauer, Leuven Belgium**
11:15 - 11:35	Coffee Break
11:35 - 12:45	**Session III (Hall A)** **Moderators: Todor Arsov, Danko Milosevic**
11:35 - 11:55	Rare Genetics and Variant Interpretation: Judging a Gene **Todor Arsov, Shtip, North Macedonia**
11:55 - 12:15	Newborn Screening for Rare Diseases in The Genomics Era **Uhr Groshelj, Ljubljana, Slovenia**
12:15 - 12:30	Contemporary HAE Treatment Paradigm in Line With Internations Treatment Guidelines **Branka Bonaci Nikolic, Belgrade, Serbia**
12:30 - 12:40	Current HAE diagnostic and treatment landscape in Macedonia **Nevenka Adjievska, Skopje, North Macedonia**
12:40 - 12:45	Discussion
12:50 - 14:00	**Session IV (Hall A)** **Moderators: Ramush Bejiqi, Urh Groshelj**
12:50 - 13:05	Vamorolone - A New, Alternative Therapeutic Option in the Treatment of DMD Patients **Danilo Nonkulovski, Skopje, North Macedonia**
13:05 - 13:20	Progressive Familiar Intrahepatic Cholestasis - New Treatment Option **Sonja Bojadzieva, Skopje, North Macedonia**

13:20 - 13:35	Growth Hormone Treatment in Dent Disease: A Case Report **Mirjana Samargjic, Podgorica, Montenegro**
13:35 - 13:50	Incidence of Antidrug Antibodies in Rheymatology Patients **Filip Gucev, Skopje, North Macedonia**
13:50 - 14:00	Discussion
14:00 - 15:00	Lunch
15:00 - 16:30	Round Table – Screening programs in SEE Moderators: Aleksandra Janchevska, Todor Arsov
	Uhr Groshelj - Ljubljana, Slovenia **Iva Bilandžija Kuš, Zagreb, Croatia** **Tatjana Milenkovic - Belgrade, Serbia Belgrade, Serbia** **Mirjana Samargjic - Podgorica, Montenegro** **Violeta Anastasovska - Skopje, North Macedonia** **Tulay Guran - Istanbul, Turkiye** **Sena Karachanak - Yankova - Sofia, Bulgaria**
16:30 - 16:45	Growth Hormone Treatment and Rare Diseases **Aleksandra Janchevska, Skopje, North Macedonia**
16:45 - 17:00	Spinal Muscular Atrophy in R.N. Macedonia: Clinical Experiences and Perspective for Early Diagnosis **Ljelja Muaremoska Kanzoska, Skopje, North Macedonia**
17:00 - 17:15	Coffee Break
17:15 - 18:00	Oral Poster Presentations Hall (B) Moderators: Vjosa Kotori, Mirjana Samardzic, Daniel Turudic

20:00	Networking Dinner

EAP - Pediatric Section of U.E.M.S

Macedonian Society
for Rare Diseases

MSRD 2025

MEETING PROGRAMME

2-4 October 2025



10th Anniversary Meeting of Rare Diseases in South Eastern Europe

& 3rd Balkan Alport Meeting

Saturday, 4 October 2025 - MEETING PROGRAMME

09:00 - 10:00	Session V (Hall A) Moderators: Filip Duma, Daniel Turudic
09:00 - 09:15	Lipodystrophy – Pediatric Perspective **Aleksandra Janchevska, Skopje, North Macedonia**
09:15 - 09:30	Lipodystrophy – An Internist's Perspective **Irfan Ahmeti, Skopje, North Macedonia**
09:30 - 09:45	Dravet syndrome – Present and Future Diagnostic and Treatment Options **Filip Duma, Skopje, North Macedonia**
09:45 - 10:00	Treatment Approach and Strategy in Refreactory Immune-Mediated TTP **Daniel Turudic, Zagreb, Croatia**
10:00 - 11:30	Oral Poster Presentations Hall (B) Moderators: Mirjana Samardzic, Danko Milosevic, Sonja Bojadzieva

Conclusion remarks
Zoran Gucev, Aleksandra Janchevska

Organizing Committee:

Zoran Gucev
Velibor Tasic
Aleksandra Janchevska
Gordana Loleska
Ivan Akimovski
Leo Spaseski
Georgi Stavreski
Ilina Treneska
Teodora Strezoska

Scientific Committee:

Zoran Gucev
Danko Milosevic
Velibor Tasic
Tatjana Milenkovic
Mirjana Samardzic
Aleksandra Janchevska
Urh Groshelj
Violeta Anastasovska
Nora Abazi Emini

Venue

Hotel Silex, Ohrid
Republic of North Macedonia

Official Language of the Meeting: English

Certificates of Attendance will be provided by Prof. V. Tasic



*Вашите пациенти што живеат со обезност имаат **волја.***
*Вие може да им понудите **начин.***

Saxenda® е 97% слична со природниот GLP-1 хормон што делува во мозокот, намалувајќи го апетитот[1-3]

Значително и одржливо намалување на телесната тежина[1,2]

Добро утврден долгорочен безбедносен профил[1,2]

Единствен лек регистриран за третман на обезност во РС Македонија

Референци: 1. Saxenda® Збирен извештај за особините на лекот. Број и датум на решението за ставање на лекот во промет: 11-10710/2 од 06.02.2025. 2. le Roux CW, Astrup A, Fujioka K, et al; for the SCALE Obesity and Prediabetes NN8022-1839 Study Group. 3 years of liraglutide versus placebo for type 2 diabetes risk reduction and weight management in individuals with prediabetes: a randomised, double-blind trial. Lancet. 2017;389(10077):1399-1409. 3. Secher A, Jelsing J, Baquero AF, et al. The arcuate nucleus mediates GLP-1 receptor agonist liraglutide-dependent weight loss. J Clin Invest. 2014;124(10):4473-4488.

Скенирајте го QR кодот за пристап до Збирниот извештај за особините на лекот.

novo nordisk®

Ново Нордиск Фарма ДООЕЛ
ул. „Никола Кљусев" бр. 11, 1000 Скопје, РС Македонија
тел.: +389 2 5800 120
www.novonordisk.com, www.novonordisk.mk
MK25SX00007, август 2025
Овој материјал е наменет само за здравствени работници.

Saxenda®
liraglutide injection

INVITED SPEAKERS

Aleksandra Gavrilovska Brzanov



Aleksandra Gavrilovska-Brzanov, MD, MSc, PhD, is a board-certified anesthesiologist and intensive care specialist with a subspecialty in pediatric anesthesia. She completed her medical education, residency training, master's degree, and doctoral studies at the "Ss Cyril and Methodius" University in Skopje. She currently serves as an Ass. Professor of Anesthesiology and Intensive Care at the Medical Faculty in Skopje, where she is actively involved in academic education, mentorship, and clinical training. In 2024, she was appointed Deputy National Transplant Coordinator of the Republic of North Macedonia. In 2025, she was selected as a national expert for the Council of Europe's working group on the "Guide on Safety and Quality in Transplantation," under the auspices of the EDQM.

Dr. Gavrilovska-Brzanov is the founder and vice president of the NGO "Young Doctors Club," a platform that promotes professional growth, advocacy, and educational empowerment among early-career medical professionals. She has participated in numerous international seminars and high-profile training programs, including the Teach the Teachers Masterclass by ESAIC. Her international experience includes medical missions in Sudan (Khartoum) under the Italian NGO "Emergency," Kuwait City, and with the International Children's Heart Foundation in the field of cardiac anesthesia. She has also completed clinical observation and education in New York (USA), France, Germany, Slovenia, Greece, Denmark, and Austria.

Dr. Gavrilovska-Brzanov has been an invited speaker at international educational events, including advanced workshops, medical seminars, and congresses in Turkey, Albania, Serbia, Bosnia and Herzegovina, Austria, and Kosovo. In addition to her clinical and teaching roles, she is a dedicated researcher involved in multiple international multicentric clinical trials and collaborative studies focusing on anesthesia, critical care, transplantation, and patient safety—contributing to the advancement of evidence-based practice in low- and middle-income countries.

KIDNEY TRANSPLANTATION IN ALPORT SYNDROME PATIENTS - CLINICAL CHALLENGES AND OUR EXPERIENCE

Aleksandra Gavrilovska Brzanov
Biljana Kuzmanovska

University Clinic for Traumatology, Orthopedic Disease, Anesthesiology, Reanimation and Intensive Care Medicine, and Emergency Department, Faculty of Medicine, Ss. Cyril and Methodius University, Skopje, RN Macedonia
Ministry of Health of the Republic of North Macedonia

Kidney transplantation currently constitutes the most effective treatment for individuals with end-stage renal illness, providing enhanced survival rates and quality of life in comparison to dialysis. As transplant outcomes have improved, indications have broadened, including elderly patients and those with significant comorbidities.

The inaugural kidney transplant in North Macedonia occurred in 1977, and subsequently, more than 520 surgeries have been conducted, predominantly utilizing living related donors. The 2013 Law on Transplantation marked a pivotal moment, facilitating the commencement of cadaveric programs in 2014. Notwithstanding constraints such as constrained critical care resources, advancements have been facilitated by heightened family consent for organ donation, the formation of multidisciplinary teams, and a gradual increase in cadaveric kidney transplantation.

Alport syndrome holds a unique position among hereditary nephropathies due to its progressive nature, extrarenal symptoms, and particular post-transplant complications. The condition arises from mutations in type IV collagen genes, resulting in structural abnormalities of the basement membrane that impact the kidney, cochlea, and eye. Patients commonly exhibit hematuria, advancing renal insufficiency, sensorineural hearing impairment, and ocular anomalies. Male individuals with X-linked disorders frequently progress to end-stage renal illness before to reaching 30 years of age.

Kidney transplantation in Alport syndrome patients has positive outcomes, as graft recurrence is not anticipated. Nonetheless, an uncommon yet severe consequence is post-transplant anti-glomerular basement membrane (anti-GBM) nephritis, which occurs in fewer than 5% of instances and can lead to swift graft failure. Awareness and early detection are essential, necessitating strong collaboration among nephrologists, immunologists, surgeons, and anesthesiologists.

From the standpoint of anesthesiology, meticulous preoperative evaluation is necessary. Auditory deficits may obstruct communication, whereas ocular and cardiovascular comorbidities should be acknowledged. Intraoperative care emphasizes the preservation of hemodynamic stability, the optimization of volume resuscitation, and the administration of non-nephrotoxic anesthetic drugs. It is advisable to utilize balanced crystalloids and goal-directed fluid therapy, supplemented by invasive monitoring, in conjunction with multimodal analgesic techniques.

In summary, kidney transplantation provides individuals with Alport syndrome the opportunity for greater longevity and enhanced quality of life. The potential danger of anti-GBM nephritis must be recognized; however, it should not deter transplantation. By combining international best practices with local experience, North Macedonia continues to expand its transplant capacity and provide hope for patients with rare genetic nephropathies such as Alport syndrome.

Keywords: Kidney transplantation, Alport syndrome, anti-GBM nephritis.

Aleksandra Janchevska



Prof. Aleksandra Janchevska, born in Skopje, after graduating from the Medical Faculty continued her education in the field of children's diseases.

She completed pediatric training and master's studies in pediatrics with a thesis on new protocols for the treatment of children with lymphoblastic leukemia. Since 2006 Aleksandra works at the Department of Endocrinology and genetics at the University Children's Hospital in Skopje. She developed her professional skills in pediatric endocrinology during numerous educational and clinical fellowships and seminars (ESPE-Great Ormond Street Hospital, EASD, EASO etc.). She has had a PhD since 2018. Aleksandra, also, finished her subspecialization of endocrinology in 2024. She actively participated as a co-investigator in 6 multicentre-rando-mised research studies with diabetic patients, patients with growth hormone deficiency (GHD) and patients with craniopharyngioma and 4 national national research studies with obese patients (children and adolescents) and children with anemia. Aleksandra is an active member of the European Society of Pediatric Endocrinology (ESPE) Obesity Working Group, International Society for Pediatric and Adolescent Diabetes (ISPAD), European Academy of Pediatrics (EAP), National and European Association of Studies in Obesity (EASO), and World Obesity Federation (WOF). She is Review Editor во Frontiers in Pediatrics, since 2022 and reviewer in several journals with a high impact factor: Frontiers in Endocrinology (6.05), Genes (4.2), Frontiers in Pediatrics (3.6), Contributions, etc.

Currently, Aleksandra is an Associate Professor at the Medical Faculty in Skopje, pediatric endocrinologist and Head of the Department of Endocrinology and genetics at the UCH, Skopje.

ACHONDROPLASIA - OUR EXPERIENCES AND PERSPECTIVES

Aleksandra Janchevska
University Children's Hospital, Medical Faculty, Skopje N Macedonia

The trend of short stature among children under 5 is decreasing worldwide, from 33% in 2000 to 22.3% now. Despite the reduced number of short children in Macedonia by 2.5 times in the last 20 years, which is not to be underestimated, still 3.4% of all children under 5 years of age have short stature.

Most of them have a proportionately short stature. As many as 90% of children with disproportionate short stature, i.e. children with skeletal dysplasia, have achondroplasia (ACH). It means 1:20,000 to 1:30,000 live births. The prevalence of ACH is 3.72/100,000 newborns per year, in Europe. The gain-of-function pathogenic variants in the Fibroblast Growth Factor Receptor 3 (FGFR3) gene cause achondroplasia. Its downstream signaling pathways lead to impaired chondrogenesis, osteogenesis, and long bone elongation. They are de novo dominant variants, of paternal origin, in about 90% of patients.

Management of ACH requires a multidisciplinary approach. Nowadays, the increased development of novel disease-modifying drugs is due to a better understanding of the genetic and molecular mechanisms of the condition. By targeting the growth plate, they stimulate chondrocyte growth and development. The novel pharmacotherapies are analogs of C-type natriuretic peptide (CNP), FGFR3-selective tyrosine kinase inhibitors, anti-FGFR3 antibodies, aptamers against FGF2, and soluble forms of FGFR3.

The early clinical recognition of these children with dwarfism, the adequate diagnostics with molecular confirmation of the genetic defect, and the discovery of new therapeutic modalities change their life course.

Keywords: Achondroplasia, Short stature, FGFR3 pathogenic variants.

LIPODYSTROPHY - A PEDIATRIC PERSPECTIVE

Aleksandra Janchevska
University Children's Hospital, Medical Faculty Skopje, N Macedonia

Lipodystrophy is a very rare and heterogeneous group of disorders characterized by a generalized or partial loss of adipose tissue. It is classified into congenital and acquired forms. Congenital generalized lipodystrophy (CGL) is a rare autosomal recessive disorder with a near-complete absence of fat from birth, leading to a distinctive physical appearance with prominent musculature and hepatosplenomegaly. Acquired generalized lipodystrophy (AGL) is often associated with autoimmune conditions and is a severe disorder with extensive fat loss. In contrast, partial forms, such as familial partial lipodystrophy (FPLD) and acquired partial lipodystrophy (APL), involve a redistribution of fat rather than a complete loss. FPLD (Barraquer-Simons syndrome) is characterized by a gradual loss of subcutaneous fat from the limbs and trunk with an accumulation of fat in the face and neck, giving a Cushingoid appearance. APL typically begins in childhood with a loss of fat from the face, neck, and upper body that progresses downwards.

The diverse clinical presentation of lipodystrophy in children, unfortunately, often leads to a delay in diagnosis. Key features include metabolic complications: severe insulin resistance, dyslipidemia, and hepatic steatosis, which can progress to non-alcoholic steatohepatitis (NASH) and also increase the risk of type 2 diabetes mellitus, pancreatitis, and cardiovascular disease at a very young age. The diagnosis in children requires a higher disease awareness and is confirmed through genetic testing, often revealing alterations in genes (AGPAT2, BSCL2, and LMNA).

Management of pediatric lipodystrophy is complex and multidisciplinary. Treatment focuses on mitigating metabolic complications and improving quality of life. Therapeutic strategies include dietary regimens, exercise, and pharmacological interventions. The use of "leptin replacement therapy", specifically metreleptin, effectively improves metabolic control in patients with generalized lipodystrophy.

An early and accurate diagnosis, coupled with a comprehensive management plan, is crucial in preventing long-term complications and improving outcomes in children with this challenging condition.

Keywords: Lipodystrophy, Children, Congenital, Acquired, Metabolic syndrome, Leptin.

GROWTH HORMONE TREATMENT AND RARE DISEASES

Aleksandra Janchevska
University Children's Hospital, Medical Faculty Skopje, N Macedonia

Growth hormone (GH) plays a vital role in human development, metabolism, and overall health. Although its primary indication is in the treatment of children with GH deficiency, a significant and growing use is in the treatment of rare diseases. These conditions often involve complex genetic and metabolic abnormalities that lead to impaired growth, developmental delays, and a range of other clinical challenges.

In children with Prader-Willi syndrome (PWS), rhGH treatment improves body composition by reducing fat mass and increasing lean body mass, while also improving linear growth and motor development. Similarly, for girls with Turner syndrome (TS), rhGH therapy is standard care, significantly improving final adult height and bone density. Furthermore, rhGH is a key component in the management of idiopathic short stature (ISS) and Noonan syndrome, where it helps stimulate growth and improve final height outcomes. The mechanism of action involves supplementing the body's natural GH, which in these diseases is either insufficient or ineffective due to complex genetic pathways.

Despite its benefits, the use of rhGH in rare diseases presents unique challenges, including the need for careful patient selection, individualized dosing, and long-term monitoring for potential side effects such as scoliosis and insulin resistance. Future research is focused on developing more personalized treatment protocols and exploring the full potential of rhGH in other rare conditions.

Keywords: rhGH treatment, Prader-Willi syndrome (PWS), Turner syndrome (TS), Noonan syndrome.

Branka Bonači Nikolić



Prof. Dr. Branka Bonaci Nikolic graduated from the Faculty of Medicine, University of Belgrade in1986. Since 1988 she is employed at the Clinic, holding different positions with increasing responsibility. In 1994 she finished her specialization and in 2000 acquired her PhD. In 2016 she was elected full professor at the Faculty of Medicine, University of Belgrade.

Among other engagements she is coordinator of the national registry for primary immunodeficiencies and hereditary angioedema.

Scientific Research & Publications: She has authored the monograph "Antineutrophil Cytoplasmic Antibodies" (2003), published over 60 authored/co-authored papers and case reports in international journals. Active member of national and international professional associations, EACCI, EADV, SGPID. Active contribution in organizing national and international congresses. Some of the Key Achievements include: Vice President (2000–2003) and President (2003–2004) of the Serbian Association of Allergologists and Clinical Immunologists, Vice President of the Serbian Group for Primary Immunodeficiencies (2019),Ministry of Science Award (2002/03) for high-impact publications (IF > 10)., Recognized for contributions to the understanding and treatment of rare immunological disorders.

CONTEMPORARY HAE TREATMENT PARADIGM IN LINE WITH INTERNATIONAL TREATMENT GUIDELINES (RECOMMENDATIONS)

Branka Bonaci Nikolic
Clinic for Allergology and Immunology, University Clinical Centre Serbia

Hereditary angioedema (HAE) is a rare autosomal dominant disorder affecting 1 in 50,000 people worldwide. HAE types I and II are caused by missense mutations in the serpin family G member 1 gene (*SERPING1*). These mutations result in impaired synthesis (HAE type I) or impaired function (HAE type II) of the C1-esterase inhibitor (C1–INH) protein. HAE is characterized by the occurrence of painful, recurrent, and unpredictable attacks that primarily affect the subcutaneous and/or submucosal tissues of the extremities, face, abdomen, and larynx, usually requiring immediate medical intervention. The disease can result in significant physical, functional, and emotional burden for patients and their families.

The ultimate treatment goal of HAE type I and II is to achieve total disease control and normalize patients' lives. International guidelines recommend that patients be evaluated for long-term prophylaxis (LTP) at every visit, taking disease activity, burden, control, as well as patient preference into consideration; guidelines also suggest that all attacks be considered for on-demand treatment (ODT). Patients treated with ODT-only or LTP with attenuated androgens (AA)/tranexamic acid (TA) or C1–INH still suffer from inadequate or sub-optimally controlled disease; limitations include breakthrough attacks from limited effectiveness and substantial side effects for AA.

It is becoming increasingly important to consider the impact of HAE from the patient perspective in order to optimize treatment. In addition to the treatment's effectiveness and tolerability, health-related quality of life (HRQoL) has now become an important health outcome indicator and a primary focus of HAE guidelines.

Keywords: Hereditary angioedema, C1-esterase inhibitor, Long-term prophylaxis.

Daniel Turudic



MD, PhD Daniel Turudich is a pediatrician at the University Hospital Centre Zagreb with clinical and research interests in pediatric hematology, nephrology, transplantation immunology, and complement-mediated diseases. I completed my medical studies (MD, University of Zagreb School of Medicine, 2016) and internship at the same institution, followed by two years as a physician in the Emergency Department before starting my pediatrics residency at the University Hospital Centre Zagreb. In parallel, I pursued a PhD at the University of Zagreb, which I successfully defended in 2025, with a thesis on decision–tree–based differential diagnosis of β-thalassemia and iron-deficiency anemia in children.

My academic work bridges data science and clinical research, with particular emphasis on complement-mediated diseases, pediatric kidney transplantation, and the application of artificial intelligence in diagnosis and risk stratification. I have authored or co-authored more than thirty peer-reviewed publications in international journals, including Nature Communications, Pediatric Blood & Cancer, European Journal of Paediatric Neurology, and the European Journal of Pediatrics, with an h-index of 9 and more than 200 citations (Scopus).

I have presented my research as an oral presentation at major international meetings, including the World Transplant Congress 2025 (San Francisco), the International Pediatric Transplant Association (IPTA) Congress 2025 (Berlin), IPNA Teaching Courses, and the European Paediatric Rheumatology Congress. For the study “HLA-DQ: The dominant driver of de novo donor-specific antibody-mediated graft failure in pediatric kidney transplantation,” I received the CareDx Congress Scientific Award at IPTA 2025. I was a member of the research team that received a Micah Batchelor Scholar Award in 2024, recognizing excellence in children’s health research.

I am a co-investigator in several phase III clinical trials investigating novel treatment options for hemophilia A and B with Pfizer and Takeda. I am also a member of JIA-COMPASS, a European multicenter research project entitled “Calprotectin Measurement for Predicting and Steering Treatment Strategies in Juvenile Idiopathic Arthritis.”

In addition, I serve as an active peer reviewer for several biomedical journals, including the British Journal of Pharmacology, PLOS ONE, Pediatric Rheumatology, BMJ Open, BMC Nephrology, European Journal of Haematology, Renal Failure, Frontiers in Pediatrics – Section Pediatric Nephrology, and Frontiers in Medicine – Section Pediatric Nephrology.

I am a member of the ESPN Working Group on Meta-Research and Quality of Evidence, the American Society of Nephrology, the American Society of Transplantation, the International Pediatric Transplant Association (IPTA), the European Society of Paediatric Oncology, the Croatian Society for Pediatric Nephrology, and several other national specialty societies. I have also contributed to the organization of regional professional meetings, including the IX South-Eastern Pediatric Nephrology Working Group meeting in Brijuni, the 2nd Croatian–Slovenian Symposium for Pediatric Nephrology, and Neonatology 2022, thereby fostering collaboration and knowledge exchange.

TREATMENT APPROACH AND STRATEGY IN REFRACTORY IMMUNE-RELATED TTP

Daniel Turudic
University Hospital Centre Zagreb, Zagreb, Croatia

Immune-mediated thrombotic thrombocytopenic purpura (iTTP) in childhood is rare, accounting for fewer than 10% of all pediatric TTPs, as the majority in children are congenital (cTTP) cases. The evidence regarding pediatric iTTPs is largely derived from case reports, registries, and small series.

Children typically present with microangiopathic hemolytic anemia and severe thrombocytopenia, often with elevated LDH and indirect hyperbilirubinemia, undetectable haptoglobin, and schistocytes on the peripheral smear. Neurologic or renal involvement may occur, but it is not universal. ADAMTS13 activity is below 10% in the presence of an inhibitor or anti-ADAMTS13 antibodies. The key differential diagnoses are hemolytic uremic syndromes (typical and atypical) and secondary thrombotic microangiopathies due to infection, drugs, malignancy, or autoimmune disease.

The treatment must not be delayed while awaiting results. First-line treatment is urgent initiation of daily therapeutic plasma exchange, which removes inhibitors and replenishes ADAMTS13. Corticosteroids are added to suppress autoantibody production, and rituximab (375 mg/m² weekly for four doses) is increasingly used upfront to reduce refractoriness and prevent relapse. Packed red blood cell transfusions should be administered as required, but platelet transfusions should be avoided unless there is life-threatening bleeding, as they can worsen thrombosis.

Refractory disease is characterized by a failure to achieve platelet recovery (platelets remaining $<50 \times 10^9$/L), ongoing hemolysis, or the development of new organ dysfunction after approximately five plasma exchange sessions, as well as by early exacerbation following an initial response, defined as a platelet count falling below 150×10^9/L. Caplacizumab, a nanobody targeting the A1 domain of von Willebrand factor, interrupts vWF–platelet binding and rapidly halts microvascular thrombosis. Caplacizumab accelerates platelet recovery, reduces the requirement for plasma exchange, and lowers the risk of mortality, relapse, and major thrombotic complications. Dosing generally follows adult regimens adapted to weight, with an initial intravenous loading dose before the first TPE, then daily subcutaneous dosing during TPE and for at least 30 days afterward. Treatment is often extended until ADAMTS13 activity recovers above 20–30% in at leas two measurements to reduce the risk of early relapse.

In highly resistant pediatric cases, other immunosuppressive agents such as cyclophosphamide, vincristine, bortezomib, or daratumumab have been used on an individualized basis, though evidence is anecdotal. Long-term monitoring of ADAMTS13 activity is important, as relapses may occur years later. Preemptive rituximab can be considered if decreased ADAMTS13 levels are detected before clinical relapse. In summary, pediatric iTTP is rare but catastrophic if unrecognized. Immediate plasma exchange and immunosuppression are life-saving, rituximab improves long-term outcomes, and caplacizumab has become an essential medication for rapid disease control in refractory cases.

Keywords: Immune-mediated thrombotic thrombocytopenic purpura (iTTP), ADAMTS13, Caplacizumab.

Danilo Nonkulovski



Assoc. Prof. Dr. Danilo Nonkulovski was born in 1984 in Bitola, North Macedonia, and completed his schooling in Resen with top results. He graduated from the Faculty of Medicine at Ss. Cyril and Methodius University in Skopje in 2009 with an average grade of 9.44/10, specialized in Pediatrics in 2018, and earned a Ph.D. in 2021 with a dissertation on procalcitonin in pediatric sepsis. He became a Research Associate in 2022 and Assistant Professor in 2023. Fluent in English, he combines clinical, academic, and research roles.

Dr. Nonkulovski began working at the University Children's Clinic in Skopje in 2011. After specialization, he served in the Neonatal and Pediatric Intensive Care Unit and, since 2020, has worked in the Department of Neurology. He completed professional training in Croatia, Turkey, and the Netherlands and held a fellowship in Pediatric Cardiology at Bambino Gesù Children's Hospital, Rome. From 2013 to 2016, he contributed to a Ministry of Health project on postoperative care for pediatric cardiac surgery patients in cooperation with the Novick Cardiac Alliance.

He has lectured to athletes, students, and medical professionals, received awards in medicine, and is a member of the Pediatric Association of Macedonia and the Macedonian Medical Society. Accredited as a lecturer and examiner, he also participates in professional exams for healthcare workers.

Currently, Assoc. Prof. Dr. Nonkulovski provides outpatient and inpatient care in Pediatric Neurology at the University Children's Clinic in Skopje and is skilled in transfontanelle CNS ultrasound in infants.

VAMOLORONE - A NEW, ALTERTNATIVE THERAPEUTIC OPTION IN THE TREATMENT OF DMD PATIENTS

Danilo Nonkulovski
PZU University Clinic for Children's Diseases, Skopje
Faculty of Medicine, University "St. Cyril and Methodius", Skopje

Duchenne muscular dystrophy (DMD) is an X-linked, genetic, progressive neuromuscular disorder caused by mutations in the DMD gene, which leads to the absence of dystrophin, a key protein for muscle function. This results in progressive muscle degeneration, loss of the ability to walk, and premature death, most often due to respiratory or heart failure.

Despite advances in symptomatic care, there is a significant need for effective drugs that will modify the course of the disease. Vamorolone is a dissociative corticosteroid that differs from other corticosteroids by a modified chemical structure that replaces the C11 hydroxyl group with a carbon-carbon double bond.

Vamorolone selectively binds to the glucocorticoid receptor, exerting anti-inflammatory effects through inhibition of NF-kB-mediated gene transcription, but leading to less transcriptional activation of other genes. Vamorolone inhibits the activation of the mineralocorticoid receptor by aldosterone. Due to its structure, vamorolone is unlikely to be a substrate of 11β-HSD and is not subject to local tissue amplification.

Vamorolone represents a significant advance in the treatment of DMD, offering the potential for long-term benefits and a new standard of care. Vamorolone was first approved in October 2023 by the US Food and Drug Administration, and in December of the same year by the EMA.

Keywords: Duchenne muscular dystrophy (DMD), Vamorolone.

Danko Milosevic



Dr. Danko Milosevich is a pediatric nephrologist, clinical researcher, and Full Professor of Pediatrics at the University of Zagreb, Croatia. Born in Brcko, Bosnia and Herzegovina, he graduated from the University of Zagreb School of Medicine in 1979, earned a master's degree in oncology in 1988, and specialized in pediatrics the following year. He later defended a doctoral dissertation on idiopathic urolithiasis in children, achieving international recognition for his work, and obtained subspecialist certification in pediatric nephrology. Over the course of his academic career, he advanced through all faculty ranks, becoming Full Professor with Tenure in 2019.

Dr. Milosevich has authored more than 70 peer-reviewed papers, with over 1,000 citations, and has published in leading journals such as Nature Communications, Journal of the American Society of Nephrology, and the European Journal of Pediatrics. He is a frequent invited speaker at international and national meetings, including IPNA teaching courses, SEPWNG, and the Rare Disease Meeting in Ohrid. He has also organized major professional events, notably serving as President of the IX South-Eastern Pediatric Nephrology Meeting in Brijuni, Croatia.

His research interests include nephrolithiasis, idiopathic nephrotic syndrome, congenital anomalies of the kidney and urinary tract, and other areas of pediatric nephrology. He has collaborated on numerous international projects, including NIH-funded studies on genetic stone disease, nephrotic syndrome, CAKUT, and autoantibodies in aHUS, and has led Croatian studies on pharmacogenomics in idiopathic nephrotic syndrome and on mirabegron therapy for pediatric enuresis.

Dr. Milosevich is Honorary President of the Croatian Pediatric Nephrology Society and an active member of several professional associations, among them the European Society for Paediatric Nephrology, the International Pediatric Nephrology Association, the European Academy of Paediatrics, the American Society of Transplantation, and the International Pediatric Transplant Association. Since 2021, he has also been a member of the Croatian Academy of Medical Sciences.

MANAGEMENT OF DISTAL RENAL TUBULAR ACIDOSIS

Danko Milosevic
University Hospital Centre Zagreb, Zagreb, Croatia

Distal renal tubular acidosis (dRTA) is a rare disorder characterized by impaired hydrogen ion secretion in the distal nephron, leading to chronic metabolic acidosis, hypokalemia, nephrocalcinosis, and progressive kidney damage. Effective management is essential to correct acid–base and electrolyte disturbances, optimize growth and bone health in children, and prevent long-term complications such as nephrolithiasis and chronic kidney disease.

The cornerstone of therapy remains lifelong alkali supplementation to normalize plasma bicarbonate. Potassium citrate and sodium bicarbonate are the most commonly used agents, with potassium salts favored in patients prone to hypokalemia and nephrolithiasis. Adequate alkali replacement not only corrects systemic acidosis but also reduces urinary calcium excretion, increases citrate levels, and slows progression of nephrocalcinosis. Regular dose adjustments are necessary in growing children, as metabolic demands increase with age.

Adjunctive management includes careful monitoring of electrolytes, growth, and renal imaging to assess nephrocalcinosis or stone formation. Nutritional support and avoidance of excessive dietary acid load further contribute to optimal outcomes. In genetic forms associated with sensorineural hearing loss, timely initiation of therapy may mitigate renal complications but requires coordination with audiological management. Advances in molecular diagnosis have also facilitated early recognition, allowing treatment before irreversible damage occurs.

Emerging therapeutic perspectives include novel alkali formulations designed to improve tolerability and adherence, a major challenge in chronic therapy, particularly in children. Future directions may involve personalized approaches guided by genotype–phenotype correlations and exploration of targeted therapies for specific molecular defects.

In conclusion, management of dRTA relies on early and sustained correction of acidosis with alkali supplementation, alongside individualized monitoring strategies. Lifelong adherence and multidisciplinary care are crucial to prevent complications and improve growth, quality of life, and renal outcomes.

Keywords: Distal renal tubular acidosis, Potassium citrate, Sodium bicarbonate, Growth, Nutrition.

Detlef Bockenhauer



Detlef Böckenhauer is a Professor of Paediatric Nephrology at University Hospital and Catholic University Leuven, Belgium, as well as Honorary Professor and Consultant Nephrologist at University College London and Great Ormond Street Hospital. He studied medicine in Germany and trained in paediatrics in Hamburg and New York City. He subsequently trained in pediatric nephrology and renal physiology at Yale University. He has worked as a clinic/academic in pediatric nephrology first at Yale, since 2004 at Great Ormond Street Hospital, London and since 2023 in Leuven. He has a special interest in the molecular basis of kidney disease, inherited kidney disease and tubulopathies.

DIAGNOSTIC CHALLENGES IN DISTAL RENAL TUBULAR ACIDOSIS

Detlef Bockenhauer
University Hospital and Catholic University Leuven, Belgium

Distal renal tubular acidosis (dRTA) is a rare disorder of renal acid–base handling, characterized by the inability of the distal nephron to adequately excrete hydrogen ions. This defect results in hyperchloremic metabolic acidosis, alkaline urine, hypocitraturia, and a tendency toward nephrocalcinosis and nephrolithiasis. While the pathophysiology is well established, diagnosis in clinical practice—especially in children—remains challenging due to heterogeneity of presentation, overlapping features with other tubular disorders, and the limitations of conventional diagnostic tools.

Patients may present with failure to thrive, growth retardation, polyuria, dehydration, or recurrent kidney stones, but these findings are nonspecific and can mimic more common pediatric conditions. Laboratory evaluation often reveals metabolic acidosis with normal anion gap and hypokalemia, yet such findings may be absent in incomplete or compensated forms of dRTA. The urine acidification test, traditionally used to confirm impaired distal urinary acidification, is invasive, poorly standardized, and difficult to perform in young children. Furthermore, incomplete dRTA—characterized by normal systemic acid–base status but persistent inability to lower urine pH—adds further diagnostic complexity.

Advances in genetic testing have expanded our understanding of inherited forms caused by variants in ATP6V1B1, ATP6V0A4, and SLC4A1, enabling earlier and more precise diagnosis, particularly in children with hearing loss or family history of nephrolithiasis. However, genetic confirmation is not universally available and may not identify all cases.

In summary, dRTA remains a diagnostic challenge due to its variable clinical expression, limitations of traditional functional testing, and overlap with other renal tubular disorders. A high index of suspicion, combined with careful biochemical evaluation and, when possible, genetic testing, is essential to ensure timely diagnosis and treatment to prevent growth impairment and chronic kidney disease.

Key words: Distal renal tubular acidosis, Hypokalemia, Hypocitraturia, Nephrocalcinosis.

NEW TREATMENT OPTIONS IN ALPORT SYNDROME

Detlef Bockenhauer
University Hospital and Catholic University Leuven, Belgium

Alport syndrome is a hereditary disorder of the glomerular basement membrane (GBM) caused by pathogenic variants in genes encoding type IV collagen (COL4A3, COL4A4, COL4A5). It is characterized by progressive kidney disease, sensorineural hearing loss, and ocular abnormalities. Despite advances in diagnosis and supportive care, affected patients frequently progress to end-stage kidney disease (ESKD), underscoring the urgent need for novel therapeutic strategies. Traditionally, renin–angiotensin–aldosterone system (RAAS) inhibition with angiotensin-converting enzyme (ACE) inhibitors or angiotensin receptor blockers (ARBs) has remained the cornerstone of treatment, effectively delaying but not preventing renal decline.

Recent years have witnessed the emergence of promising new treatment modalities. Sodium–glucose cotransporter 2 (SGLT2) inhibitors, initially developed for diabetes and chronic kidney disease, are now being investigated in Alport syndrome due to their nephroprotective and antifibrotic effects. Endothelin receptor antagonists, such as atrasentan, are also under evaluation in clinical trials, showing potential in reducing proteinuria and slowing disease progression. Additionally, bardoxolone methyl, an activator of the Nrf2 pathway, has demonstrated favorable effects on kidney function in Alport patients, though long-term safety and efficacy require further validation.

Beyond pharmacological therapies, molecular approaches are gaining momentum. Gene therapy, exon skipping, and RNA-based strategies aim to restore or compensate for defective collagen IV synthesis. Stem cell–based therapies and approaches targeting GBM repair are also under preclinical exploration. Importantly, earlier diagnosis through genetic testing enables timely initiation of therapy, improving long-term renal outcomes.

In conclusion, while conventional RAAS blockade remains the standard of care, multiple innovative therapeutic strategies are on the horizon. The integration of SGLT2 inhibitors, endothelin antagonists, and emerging molecular therapies holds promise to transform the management of Alport syndrome, with the ultimate goal of delaying or preventing ESKD.

Key words: Alport syndrome, Treatment, ACE inhibitors, Atrasentan, SGLT2 inhibitors.

MEET THE EXPERT SESSION ON X-LINKED HYPOPHOSPHATEMIA

Moderators: Velibor Tasic (Skopje, North Macedonia), Nora Abazi Emini (Skopje, North Macedonia)
Expert: Detlef Bockenhauer (Leuven, Belgium, UK)

Background: X-linked hypophosphatemia (XLH) is the most common inherited form of rickets and serves as a model of rare metabolic bone disorders. Caused by mutations in the PHEX gene, XLH leads to increased fibroblast growth factor 23 (FGF23) activity, renal phosphate wasting, and impaired bone mineralization. Advances in molecular understanding and treatment have transformed patient care, but many clinical challenges remain.
Objectives: This interactive session will address critical questions in the diagnosis and management of XLH, with insights from an international expert.
Discussion Points:

- Early recognition and differentiation of XLH from nutritional rickets and other hypophosphatemic disorders.
- Long-term complications, including growth impairment, skeletal deformities, dental abnormalities, and nephrocalcinosis.
- Pathophysiological mechanisms: PHEX mutations, FGF23 excess, and potential genotype–phenotype correlations.
- Therapeutic strategies: comparison of conventional therapy (phosphate and active vitamin D) with burosumab, including efficacy, safety, and challenges in adolescents and adults.
- Multidisciplinary aspects of care, focusing on orthopedic and dental management.
- Future perspectives: unmet needs, emerging therapies, and areas for further research.

Conclusion: This “Meet the Expert” session will provide an opportunity to discuss practical and conceptual issues in XLH with Prof. Detlef Bockenhauer, offering clinicians updated knowledge and guidance for optimizing patient outcomes across all ages.

Key words: X-linked hypophosphatemia, Rickets, Phosphate metabolism, FGF23, Burosumab, Rare disease.

Filip Duma



Dr. Filip Duma (b. July 15, 1955, Bitola, Macedonia) is a Macedonian physician, pediatrician, and pediatric neurologist. He earned his M.D., pediatric specialization, and Ph.D. in Medical Sciences at the University of "Ss. Cyril and Methodius," Skopje.

Dr. Duma completed advanced training at the Child Clinic in Ljubljana (1987), London's National Institute for Child Health (1989), Children's Memorial Hospital in Chicago (1992–1993, Fulbright), and the Royal Prince Alfred Hospital in Sydney (2000).

Beginning his career at the Pediatrics Clinic in Skopje in 1980, he became a pediatric specialist in 1985, pioneered brain ultrasound in Macedonia, and focused on pediatric neurology from 1987 onward. He has lectured at the First Balkan School for Ultrasound, served as assistant professor and scientific collaborator at the Medical University of Skopje, and contributed to major projects in developmental pediatrics, early diagnosis, and treatment of high-risk children. Dr. Duma introduced video EEG to Macedonia in 2005, led the 2009 "Child Neurology Meets" conference, and from 2012 to 2018 was Deputy President of the Macedonian Medical Association.

He is the author of a doctoral thesis on neonatal intracranial hemorrhage, published in 1997, and has collaborated with NIH on studies of febrile convulsions. Though retired since July 2022, he continues as a pediatric neurology consultant at Neuromedika, Skopje, and Bamby Medical, Strumica.

DRAVET SYNDROME - PRESENT AND FUTURE DIAGNOSTIC AND TREATMENT OPTIONS

Filip Duma
Neuromedika, Skopje

Dravet syndrome is a rare and severe form of epilepsy and developmental encephalopathy that begins in infancy, typically between 6-12 months of age. It is a genetic disorder, with most cases caused by mutations in the SCN1A gene. The condition is characterized by prolonged, drug-resistant seizures, particularly febrile seizures, that evolve into multiple seizure types. Dravet syndrome, also, involves developmental delays, intellectual disability, ataxia, language and visual-perceptual problems and behavioral issues, and carries a risk of sudden unexpected death in epilepsy (SUDEP).

Early diagnosis (genetic testing) and treatment can improve outcomes and quality of life.

Currently available treatments: In recent years, several new anti-seizure medications have gained approval for Dravet syndrome (Fenfluramine (Fintepla), Cannabidiol (Epidiolex), Stiripentol (Diacomit)).

A number of promising treatments for Dravet syndrome are in development, including gene therapies (Zorevunersen (STK-001): An antisense oligonucleotide (ASO), ETX101: A gene regulation therapy, AAV gene replacement) and repurposed drugs (non-genetic therapies).

Other options: The ketogenic diet and vagus nerve stimulation (VNS) are also used to help manage seizures.

Non-compliant drugs: traditional sodium channel blockers are generally contraindicated as they can worsen seizures.

The encephalopathy starts to develop slowly after the first seizures, and it is mostly irreversible.

The importance of early diagnosis and appropriate treatment is directly connected to the epilepsy outcome and the quality of life. Febrile seizures, if not interpreted properly, can be misleading factors for early diagnosis.

Improving awareness for this rare disease, which is often misdiagnosed and treated as febrile seizures.

Genetic testing for the SCN1A gene is available and a must.

Early introduction of proper treatment in reducing the seizures and postponing encephalopathy.

New treatments and their potential in treating resistant epilepsy and preventing encephalopathy.

Keywords: Epileptic encephalopathy, DRE (drug resistant epilepsy), Genetic testing , Gene therapies

Filip Gucev



Filip Guchev was born in 1981 in Skopje. From 1993 to 1996 he lived and studied in Portland, Oregon, USA, where he received an award for best student from President Clinton. He graduated from the Faculty of Medicine in Skopje in 2006 as the top student of his class. For this achievement, he received recognition from the Rectorate of the University "St. Cyril and Methodius," as well as from the Macedonian Medical Association.

He completed his specialization in internal medicine in 2010, after which he was employed at the Clinic of Rheumatology. In 2011 he undertook an educational stay at the Clinic of Rheumatology in Ljubljana, Slovenia, where he also trained in ultrasound diagnostics of the musculoskeletal system. In 2014 he worked as an internist-rheumatologist at Seychelles Hospital, Victoria, Seychelles. In 2015 he worked as a rheumatologist at Al-Amiri Hospital, Kuwait City, Kuwait. From 2017 to 2020 he was Director of the University Clinic of Rheumatology in Skopje. During this period, a large number of biological and targeted therapies for the treatment of rheumatology patients were introduced, the clinic was renovated, and new equipment was acquired. In 2023 he earned his PhD at the Faculty of Medicine in Skopje and was elected Assistant Professor of Internal Medicine and Rheumatology.

He has been the principal investigator of two randomized, multicenter studies, as well as sub-investigator in three other such studies.

His expertise includes the use of biological and targeted therapies, diagnosis and treatment of patients with rare diseases, ultrasound diagnostics and procedures of the musculoskeletal system, immunofluorescent and polarization microscopy.

INCIDENCE OF ANTIDRUG ANTIBODIES IN RHEUMATOLOGY PATIENTS

Filip Guchev
University Clinic of rheumatology, University "Sts.Cyril and Methodius", Skopje, Macedonia.

The use of biologic therapy in rheumatology patients has become routine since its introduction about 30 years ago. This opens new questions about its long-term efficiency and safety. For example, an immune reaction may occur that can reduce the drug's efficacy and potentially lead to adverse side effects. The immunogenicity of these drugs can be evaluated by detecting and measuring antibodies that have been produced against these drugs. In fact, antidrug antibodies (ADA) are increasingly used in rheumatology in monitoring therapeutic response. We present an overview of the immunogenicity of biological agents used in autoimmune rheumatic diseases highlighting the incidence of anti-drug antibodies at the University clinic of rheumatology in Skopje.

Seventy-eight patients were tested for the generation of antidrug antibodies to adalimumab, etanercept and rituximab treated at the university clinic of rheumatology in Skopje, Macedonia. We investigated the effects of treatment duration, diagnosis, drug and synthetic DMARD use in the generation of antidrug antibodies.

We tested 78 patients treated with rituximab, etanercept and adalimumab for antidrug antibodies. Mean duration of biologic treatment for all patients was 44,38 months and mean ADA was 95,70AU/ml (cut-off 10AU/ml). Mean antidrug antibodies for rituximab, etanercept and adalimumab were 238AU/ml, 13,29AU/ml and 25,74AU/ml, with mean duration of therapy 64,85, 40 and 28,66 months respectively. Mean antidrug antibodies for patients with rheumatoid arthritis, ankylosing spondylitis and psoriatic arthritis were 157,1AU/ml, 7,34AU/ml and 6,54AU/ml, with mean duration of therapy 49,75, 40,69 and 35,1 months respectively. We found a positive correlation to the occurrence of antidrug antibodies to duration of treatment (Pearson Correlation 0,329, $p<0,005$), but not due to the use of synthetic DMARDs together with biologic therapy (Pearson Correlation 0,121, $p=0,292$).

Biologic DMARDs can induce immunogenicity, especially the development of ADAs. It may be important to report the amount of ADA in patients in addition to the percentage of patients who develop ADAs. Several studies have shown that ADAs occur in low frequency and low titer and do not affect the safety or efficacy of biologics. Regardless, the immunogenicity potential of biologics agents should be considered as a part of good clinical practice, not only because ADAs can interfere with the efficacy of biologics but also because they increase the risk of adverse events.

Keywords: Biologic therapy, Antidrug antibodies (ADA), immunogenicity.

Irfan Ahmeti



Irfan Ahmeti is an internist - endocrinologist, employed at the Faculty of medicine, Director of University clinic of Endocrinology, Diabetes and Metabolic Disorders, Skopje. He is the head of the Diabetes Center department. Currently, he is the president of the Scientific Association for Obesity - OBEM, as well as the vice-president of the Scientific Association of Endocrinologists and Diabetologists of Macedonia. Since 2017 is a PhD of endocrinology - diabetology. He is also a member of the European Association for the Study of Obesity (EASO). It is a signatory to the Venice Declaration – 2024 as advocacy statement for obesity. He is the author and co-author of over 60 professional papers published in the country and abroad. He is the author and editor of the National Obesity Guidelines 2025 as well as the author of the National Guidelines for Diabetes 2023. He is the author of 2 books on diabetes, author of chapters and reviewer of 2 books on diabetes. He is a member of the editorial board of Medicus article. He attended professional training in renowned university centers such as Zagreb, Rome and Paris.

LIPODISTROPHY - AN INTERNIST'S PERSPECTIVE

Irfan Ahmeti
University Clinic of Endocrinology, Diabetes and Metabolic Disorders, Ss. Cyril and Methodius University, Skopje, North Macedonia

Lipodystrophy syndromes are a heterogeneous group of rare disorders characterized by partial or generalized absence of adipose tissue, often accompanied by severe metabolic complications including insulin resistance, diabetes mellitus, hypertriglyceridemia, hepatic steatosis, and premature cardiovascular disease. Although many forms manifest during childhood or adolescence, internists frequently encounter these patients in adulthood, either due to delayed recognition or during transition from pediatric to adult care.

From the internist's perspective, lipodystrophy represents both a diagnostic and therapeutic challenge. The condition may be overlooked in adults presenting with striking muscularity, severe metabolic syndrome at a young age, or treatment-resistant diabetes and dyslipidemia. A high index of suspicion, coupled with careful clinical examination and genetic or immunologic testing, is essential for accurate classification into congenital or acquired forms. Adult patients often present with advanced hepatic or cardiovascular involvement, emphasizing the importance of comprehensive and multidisciplinary care.

Management strategies in adults include strict lifestyle modification, pharmacological treatment of metabolic complications, and regular monitoring for organ damage. Metreleptin, a recombinant leptin analog, has become the first disease-specific therapy, demonstrating significant improvement in glycemic control, hypertriglyceridemia, and hepatic steatosis in generalized lipodystrophy. For partial forms, evidence is emerging, and other novel metabolic and gene-targeted therapies are under investigation.

For the internist, awareness of lipodystrophy is crucial, as timely diagnosis may prevent complications and provide access to disease-specific interventions. Coordinated, lifelong, multidisciplinary management can substantially improve quality of life and long-term prognosis for affected individuals.

Keywords: Lipodystrophy, Internist, Leptin therapy, Metabolic complications, Rare diseases.

Ljelja Muaremoska Kanzoska



Dr. Ljelja Muaremoska Kanzoska is a pediatrician and pediatric neurologist with extensive experience in the diagnosis and treatment of neuromuscular disorders and epilepsy in children. Born in 1984 in Prilep, North Macedonia, she earned her medical degree from the Faculty of Medicine at "Ss. Cyril and Methodius" University in Skopje in 2009, later completing specialization in pediatrics and subspecialization in child neurology. She currently heads the Department for Nervous and Neuromuscular Disorders at the University Clinic for Children's Diseases in Skopje.

Throughout her career, Dr. Muaremoska Kanzoska has been actively involved in advancing care for children with spinal muscular atrophy (SMA) and other rare neurological conditions. She has trained in leading European and Israeli centers, including workshops on intrathecal administration of Nusinersen and comprehensive management of SMA. She regularly lectures at professional and scientific meetings across Europe and has contributed to numerous publications on neuromuscular diseases, epilepsy, and rare genetic syndromes.

Her research portfolio includes studies on early SMA treatment in North Macedonia, genotype–phenotype correlations in neurofibromatosis type 1, and genomic diagnostics in pediatric epileptology. She is a member of several professional associations, including the Macedonian Pediatric Association and Treat-NMD, and speaks English as well as basic Turkish and Albanian. Dr. Muaremoska Kanzoska remains dedicated to improving the quality of life for children with complex neurological and neuromuscular conditions through early diagnosis, innovative therapies, and multidisciplinary care.

SPINAL MUSCULAR ATROPHY IN R.N.MACEDONIA: CLINICAL EXPERIENCES AND PERSPECTIVES FOR EARLY DIAGNOSIS

Ljelja Muaremoska Kanzoska
University clinic for pediatric diseases, Skopje, R.N.Macedonia

Spinal muscular atrophy (SMA) is a rare, autosomal recessive neuromuscular disorder caused by biallelic mutations in the SMN1 gene, leading to deficiency of the survival motor neuron (SMN) protein and progressive degeneration of alpha motor neurons in the anterior horns of the spinal cord. The clinical spectrum ranges from severe, early-onset forms with markedly reduced life expectancy to milder, later-manifesting phenotypes. Over the past decade, three disease-modifying therapies have been developed, fundamentally changing the natural history of the disease by enabling stabilization and functional improvements previously considered unattainable. The Macedonian experience encompasses the implementation of intrathecal therapy administration in clinical practice, achieving high procedural success and a safety profile consistent with international data. The use of radiologically assisted techniques provides reliable access in patients with severe scoliosis or complex spinal anatomy, thereby minimizing adverse effects. Another crucial aspect is the importance of early diagnosis. Numerous studies confirm that presymptomatic or early symptomatic treatment results in superior motor and cognitive outcomes compared to late initiation, emphasizing the need to establish a neonatal screening program in our country. Such a strategy would not only ensure timely initiation of therapy but also contribute to harmonizing standards of care in line with European recommendations. This work presents Macedonian clinical experiences in the treatment of SMA, discusses the practical aspects of intrathecal administration, and highlights the perspectives of neonatal screening as a prerequisite for achieving optimal therapeutic outcomes and integrated patient care.

Keywords: Spinal muscular atrophy, Rare disease, Clinical experience, Early diagnosis.

Martin Magner



Professor Martin Magner, MD, PhD, MBA, serves at the Department of Paediatrics and Inherited Metabolic Disorders, where his clinical and research focus lies in the realm of inherited metabolic conditions and autism spectrum disorders. Certified in Paediatrics, Medical Genetics, Clinical Nutrition, and Intensive Metabolic Care, he has authored or co-authored over 130 scientific publications, including more than 60 in impact-factor journals. Professor Magner has contributed to the identification of several novel genetic diseases and acts as principal investigator in numerous clinical trials.

FOUNDER MUTATIONS AND RARE GENETIC DISORDERS IN ROMA POPULATIONS OF CENTRAL AND EASTERN EUROPE

Martin Magner
Department of Paediatrics and Inherited Metabolic Disorders, General University Hospital and First Faculty of Mecidine, Charles University, Prague, Czech Republic

Roma populations in Central and Eastern Europe exhibit a distinct set of rare monogenic disorders, many of which are linked to founder mutations and genetic isolation. This presentation focuses on conditions with elevated prevalence in Roma communities.

(1) TMEM70-related mitochondrial ATP synthase deficiency is caused by the prevalent c.317-2A>G mutation. It presents in the neonatal period with metabolic decompensation, lactic acidosis, hyperammonemia, and 3-methylglutaconic aciduria, often accompanied by cardiac and respiratory failure. Long-term prognosis depends on early recognition and management of hyperammonemic crises.

(2) EGFR-related ectodermal dysplasia, due to the loss-of-function mutation c.1283G>A (p.Gly428Asp), manifests in neonates with thin, translucent, and fragile skin, ichthyosis, and recurrent infections. The prognosis is generally poor.

(3) Neuronal ceroid lipofuscinosis type 7 (CLN7) is a neurodegenerative disorder characterized by developmental delay or regression, progressive vision loss due to pigmentary retinopathy, and epilepsy. In Roma populations, the most frequent form is the late-infantile variant caused by the homozygous c.881C>A (p.Thr294Lys) mutation in the MFSD8 gene.

(4) Congenital myasthenic syndrome due to CHRNE mutation involves the ε1267delG deletion in the epsilon subunit of the acetylcholine receptor. It typically presents in the neonatal or early infant period with hypotonia, weak cry, facial muscle weakness, poor feeding, and failure to thrive. Symptoms respond well to acetylcholinesterase inhibitors.

(5) GPD1 deficiency, caused by the c.895G > A (p.Gly299Arg) mutation in the GPD1 gene, leads to impaired glycerol-3-phosphate metabolism. Clinically, it presents with neonatal hypertriglyceridemia, hepatomegaly, steatosis, and elevated liver enzymes. Though underdiagnosed, it is increasingly recognized in Roma neonates and may mimic more common metabolic disorders.

(6) Renal hypouricemia (RHUC) is caused by an inherited defect in the main reabsorption system of uric acid due to variants c.1245_1253del and c.1400C>T in the SLC22A12. RHUC is characterized by a decreased serum uric acid concentration and an increase in its excreted fraction. Patients suffer from hypouricemia, hyperuricosuria, urolithiasis, and even acute kidney injury.

(7) Cystinuria is an autosomal recessive disorder manifesting by urolithiasis caused by defective transport of cystine and dibasic amino acids in the proximal renal tubules and small intestine. The most common mutation in Roma population is T216M inSLC3A1.

These conditions exemplify the clinical relevance of founder mutations in genetically isolated populations. Their identification underscores the importance of targeted molecular diagnostics and mutation-specific awareness in regions with concentrated Roma communities.

Keywords: Rare monogenic disorders, Founder mutations, Roma population.

Mira Samardžić



Prof. Dr. Mira Samardzic is a specialist in pediatrics and pediatric endocrinology with a distinguished career spanning more than four decades. She graduated from the Faculty of Medicine in Belgrade in 1979 and completed her pediatric specialization in 1988 at the University Clinic "Rebro" in Zagreb. Between 1987 and 1991, she pursued postgraduate specialist studies in clinical pediatrics, pediatric endocrinology, and metabolism at the Faculty of Medicine, University of Zagreb. She earned her master's degree in 1994 and her doctoral degree in 1999 from the Faculty of Medicine in Belgrade.

Prof. Samardzic has complemented her academic training with numerous educational programs in Montenegro and abroad, focusing on pediatrics, pediatric endocrinology, and rare diseases. Since 1992, she has been part of the medical team at the Institute for Children's Diseases in Podgorica, and in 2023 she joined the Polyclinic MojLab. In recognition of her professional and academic contributions, she was appointed a full professor at the Faculty of Medicine in Podgorica in 2017.

Through her long-standing dedication to clinical practice, teaching, and research, Prof. Dr. Mira Samardzic has made a significant impact on the development of pediatric endocrinology and the care of children with rare and complex diseases in Montenegro and the region.

GROWTH HORMONE TREATMENT IN DENT DISEASE: A CASE REPORT

Mira Samardzic[1], Snezana Pavicevic[2].
[1]*Polyclinic Moj Lab, Podgorica, Montenegro*
[2]*Institute for Sick Children, Podgorica, Montenegro*

Introduction: Dent's disease is an X-linked recessive proximal tubulopathy characterized by low molecular weight proteinuria, hypercalciuria, nephrocalcinosis, nephrolithiasis and progressive renal failure. Common features are also rickets or osteomalacia, growth retardation, and short stature. To date, few reports have suggested positive effect of growth hormone (GH) therapy without adverse events on kidney function in children with poor growth associated with Dent's disease.

Case presentation: We report a 6.6-year-old Montenegrin boy with proteinuria, hypercalciuria, nephrocalcinosis, rickets and short stature (-2.89 SD) with unimpaired growth hormone secretion. Parental adjusted height was – 3 SD; Molecular genetic analysis showed S244L substitution on the CLCN5 gene. After two years of conventional treatment with hydrochlorothiazide, laboratory tests revealed more prominent proteinuria, mild hypophosphatemia, increased values of alkaline phosphatase and features of rickets. Phosphate salts, calcitriol, potassium citrate and growth hormone were included in the therapy. At the last evaluation at 17.8 years of age, height was 175 cm (M), weight was 72 kg, BMI- 23.4 kg/m^2 (M-+1 SD) and pubertal status was Tanner Stage 5.

His global kidney functions and levels of proteinuria and calciuria remained relatively stable. In spite of the growth hormone therapy, his tubular reabsorption of phosphate slightly deteriorated.

Conclusion: Treatment with recombinant human growth hormone has a positive effect on the final height in poorly growing children with Dent's disease and hypophosphatemic rickets. However, it is not possible to reach definite conclusions due to the small sample in the literature and the short duration of the therapy.

Keywords: Dent's disease, CLCN5 gene mutation, Hypophosphatemic rickets.

Nevenka Adjievska



Dr. Nevenka Adjievska graduated at the Medical Faculty, Plovdiv, Bulgaria in 2006. Since 2008 she is employed at the Clinic, holding different positions with increasing responsibility. As of 2014 she is Dermatology Specialist. From 2024 on she is Head of Pediatric Dermatology Department.

Current involvement in rare disease segment includes being Member of Rare Diseases Team (Hereditary Angioedema – ACARE certified) and Member of national guideline development groups (HAE, Atopic Dermatitis).

Scientific Research & Publications : She has acted as Investigator in COVID-19 and Psoriasis clinical studies, published over 30 authored/co-authored papers and case reports in international journals, as well as Presented at EADV Congresses, ISA Munich, and national/international symposia on multiple topics including: Lupus, Psoriasis, Pediatric Dermatology, Vaccine Allergies. Active member of national and international professional dermatology associations: Macedonian Dermatology & Aesthetic Medicine Associations, European Academy of Dermatology and Venereology (EADV), International Society of Pediatric Dermatology (ISPD).

CURRENT HAE DIAGNOSTIC AND TREATMENT LANDSCAPE IN MACEDONIA

Nevenka Adjievska
University Clinic of Dermatology, Skopje

HAE Type I is the most commonly diagnosed form in North Macedonia, with patients typically experiencing symptom onset around age 11 and a diagnostic delay averaging 7 years . Clinical severity varies, with patients reporting an average of 31 attacks per year, and laryngeal attacks being treated 100% of the time. Unmet needs include:

- Limited awareness among non-specialist physicians.
- Delayed diagnosis and inconsistent implementation of international guidelines.
- Financial barriers to accessing long-term prophylaxis

Opportunities lie in:

- Expanding education and training for healthcare providers.
- Strengthening collaboration between patient organizations and industry.
- Enhancing registry participation and genetic screening.

Keywords: HAE Type I, Diagnostic delay, Clinical severity.

Nikola Ilic



Dr. Nikola Ilic is a pediatrician and clinical geneticist actively engaged in the diagnosis and management of children with developmental disorders and rare diseases. He graduated from the Faculty of Medicine, University of Belgrade, where he also completed his specialization in pediatrics. Currently, he works at the Institute for Mother and Child Healthcare of Serbia, Belgrade, where he combines clinical practice with genetic diagnostics and multidisciplinary care for patients and their families.

His professional focus includes neurodevelopmental disorders, intellectual disability, skeletal dysplasias, cardiogenetics, and dysmorphology. He has authored and co-authored several scientific papers in international peer-reviewed journals and has presented his research at various national and international conferences. Dr. Ilic is an active member of the European Society of Human Genetics (ESHG).

In his recent research, he has been particularly involved in the application of artificial intelligence in the interpretation of genomic data and the prediction of diagnostic outcomes in children with global developmental delay and intellectual disability. His work bridges clinical practice, genomic technologies, and emerging AI tools, with the aim of improving diagnostic yield and advancing personalized medicine in the field of rare diseases.

DIAGNOSIS AND TREATMENT OF INHERITED BONE DISEASES

Nikola Ilic
Clinical Genetics Outpatient Clinic, Mother and Child Health Care Institute of Serbia "Dr Vukan Cupic", 11070 Belgrade, Serbia

Inherited bone diseases represent a heterogeneous group of rare disorders characterized by disturbances in skeletal growth, bone density, and structural integrity. Advances in genomic technologies, particularly whole-exome sequencing (WES) and targeted gene panels, have substantially improved diagnostic accuracy, enabling the identification of causal variants in an increasing proportion of patients. Early and precise genetic diagnosis not only clarifies the underlying etiology but also guides clinical management, genetic counseling, and prognosis.

The therapeutic landscape has also evolved in recent years. While supportive care and orthopedic interventions remain cornerstones of management, novel treatment strategies are emerging. These include enzyme replacement therapies, antisense oligonucleotides, and small molecules targeting dysregulated pathways in osteogenesis. Moreover, ongoing research into repurposed drugs and gene-based therapies offers promising horizons for conditions previously considered untreatable.

This lecture will provide an overview of current diagnostic approaches and challenges, highlight illustrative clinical cases, and discuss state-of-the-art therapeutic options. Special emphasis will be placed on the role of precision medicine in tailoring interventions for individual patients and on the importance of multidisciplinary care in improving outcomes for children affected by inherited bone diseases.

Keywords: Inherited bone diseases, Skeletal dysplasias, Genomic medicine, Precision therapy, Rare diseases.

Nikolina Smokovska



Dr. Nikolina Smokovska is a specialist nephrologist and Chief Clinic Doctor at PHI Diaverum in Skopje, North Macedonia. She earned her medical degree from the University “Ss. Cyril and Methodius” in Skopje, followed by a specialization in internal medicine and a subspecialization in nephrology. Dr. Smokovska has extensive experience in the management of chronic kidney disease, hemodialysis, and patient-centered care in renal replacement therapy.

Throughout her career, she has actively contributed to nephrology research and education, presenting her work at numerous international and regional congresses, including ERA-EDTA, BANTAO, and the Macedonian Society of Nephrology, Dialysis, Transplantation, and Artificial Organs. Her research focuses on optimizing hemodialysis parameters, improving outcomes in chronic dialysis patients, and individualized approaches to dialysis therapy. She has authored multiple publications in peer-reviewed journals, covering topics such as bone disease in dialysis, recovery time after hemodialysis, and phosphorus management in high-flux dialysis.

Dr. Smokovska is an active member of several professional organizations, including the Macedonian Medical Society, ERA-EDTA, the International Society of Nephrology, and serves on the editorial board of the BANTAO Journal. She has received multiple ERA travel grants and awards for her research and contributions to nephrology education. Beyond her professional work, she has interests in travel, mountaineering, and cycling.

DIALYSIS TREATMENT - MODALITIES AND UPDATES

Nikolina Smokovska
Diaverum North Macedonia

Hemodialysis (HD) is the predominant life-sustaining therapy for over three million people worldwide with End-Stage Kidney Disease (ESKD). Conventional thrice-weekly, 4-hour in-center HD effectively removes small toxins and excess fluid but fails to mimic continuous kidney function, contributing to cardiovascular morbidity and mortality. In the past two decades, HD has evolved toward a more physiologic, personalized, and patient-centered approach.

Key treatment modalities have driven this transformation. High-Flux Hemodialysis (HF-HD) improved clearance of middle molecules, while Online Hemodiafiltration (HDF) combines diffusive and convective clearance with proven survival and cardiovascular benefits. Expanded Hemodialysis (HDx) uses medium cut-off membranes, offering HDF-like clearance without substitution fluid. Adjusting treatment schedules with frequent or nocturnal HD enhances blood pressure and phosphate control, regresses left ventricular hypertrophy, and improves quality of life. Home Hemodialysis (HHD) empowers patients with flexibility and independence, supported by user-friendly machines.

Technological tools further enable individualization. Bioimpedance spectroscopy and relative blood volume monitoring optimize fluid management, reducing overload and hypotension. Online clearance monitoring (OCM) ensures real-time dialysis adequacy and immediate dose adjustment.

Emerging innovations include wearable and implantable artificial kidneys for continuous portable therapy, integrating sorbent technology and bio-hybrid components to restore metabolic and endocrine functions. Artificial intelligence and machine learning are increasingly applied to predict complications and support dynamic, personalized prescriptions.

Modern HD has progressed from a rigid, standardized procedure to a sophisticated, individualized therapy. By combining advanced modalities, optimized treatment schedules, and cutting-edge technology, the field now focuses not only on survival but also on improving long-term outcomes and quality of life for people with ESKD.

Keywords: Hemodialysis, End-stage kidney disease, Personalized therapy, Online hemodiafiltration, Home hemodialysis.

Nora Abazi Emini



Nora Abazi Emini, born in 1976 in Gostivar, Republic of North Macedonia, is a pediatric nephrology subspecialist with over two decades of medical experience.

She earned her medical degree from the Faculty of Medicine in Skopje in 2002. She completed her specialization in pediatrics in 2011 and obtained a subspecialty in pediatric nephrology in 2023. Since 2013, she has been affiliated with the Department of Nephrology at the University Children's Hospital Skopje, where she has served as Head of Department since 2022.

Her clinical expertise includes congenital anomalies of the urinary tract, rare hereditary kidney diseases, and glomerular and tubular disorders. She has actively contributed to numerous national and international research projects, scientific meetings, and congresses, and has authored and co-authored several publications in professional journals. She also serves as the national representative for the European Registry for Children on Renal Replacement Therapy (ESPN/ERA).

PRIMARY HYPEROXALURIA TYPE 1– EARLY ONSET PRESENTATION

Nora Abazi Emini
Department of Pediatric Nephrology, University Children's Hospital, Skopje, North Macedonia

Primary hyperoxaluria (PH) is a rare autosomal recessive disorder characterized by hepatic overproduction of oxalate, leading to progressive renal impairment and systemic complications. Early manifestations often present in infancy or early childhood and include recurrent nephrolithiasis, nephrocalcinosis, and urinary tract infections. In its most severe form—infantile oxalosis—patients may rapidly progress to end-stage renal disease (ESRD) within the first months of life due to high oxalate burden and immature renal clearance. This can result in systemic oxalosis, where calcium oxalate crystals deposit in extrarenal tissues such as bones, retina, myocardium, and vascular structures, causing multisystem damage. Clinical signs may include failure to thrive, vomiting, hematuria, nephrocalcinosis, and radiographic evidence of crystal deposition. Early diagnosis through metabolic screening and genetic testing is essential to initiate timely interventions. New RNA interference therapies represent a transformative advance in PH1 management, significantly lowering hepatic oxalate production and potentially delaying or preventing progression to systemic oxalosis.

Keywords: Primary hyperoxaluria, Infantile oxalosis, Renal impairment, Nephrocalcinosis, Genetic testing.

KIDNEY CYSTS AND ALPORT SYNDROME

Nora Abazi Emini
Department of Pediatric Nephrology, University Children's Hospital, Skopje, North Macedonia

Alport syndrome is a hereditary condition caused by mutations in the *COL4A3*, *COL4A4*, or *COL4A5* genes, which disrupt the production of type IV collagen—a key structural component of basement membranes in the kidneys, ears, and eyes. The disorder is classically characterized by progressive kidney failure, hearing impairment, and ocular abnormalities.

Recent findings have highlighted the presence of kidney cysts in individuals with Alport syndrome. These cysts are thought to result from structural weakening of the glomerular and distal tubular basement membranes due to defects in the collagen IV α3α4α5 network. This weakening leads to localized distension and cyst formation.

Although typically small, few in number, and asymptomatic, these cysts may serve as indicators of disease progression and an elevated risk of renal failure. They generally do not impair kidney function or require specific treatment. Therefore, in patients with unexplained kidney cysts, especially when polycystic kidney disease is excluded, genetic testing should include *COL4A3–COL4A5* variants to assess for underlying Alport syndrome.

Keywords: Alport syndrome, Kidney cysts, Genetic testing.

Ramush Bejiqi



Ramush Bejiqi was born in 1961, in Rama Baje, Medvedja, Yugoslavia. He has graduated in medicine 1981-1986 at the Medical Faculty in Nish, Serbia, where he completed Master of Sciences Imunology and Alergology, (1986 – 1988). He has also finished has pediatric residency (5 years) in Nish, Serbia (1991 – 1995), as well as felow sheep in cardiology (2 years) in Belgrade, Serbia (1995 – 1997). He defended his PhD in the area of congenital heart disease titled: "Congenital Heart Disease in Neonates with Central Cyanosis" in Tirana, Albania (2010). He was trained in transthoracic echocardiography, transesophageal echocardiography, 3D, 4D. fetal echocardiography, interventional pediatric cardiology and abdominal echosonography. He started his professional career in 1986-1991 at Medical Center, Leskovac, Medvedja, Serbia. From 1991 and onward he is employed at the Pediatric Clinic, University Clinical Center of Kosovo, Prishtina, Kosovo. He has finished trainning in the area of Pediatrics Cardiology and fetale echocardiography in many European una USA centers. He is head of Pediatrics Cradiology Departament in Prishitna and Consulting pedutrics cardiology and fetal echocardiography in many Balkans regjional Centers. He has learned from international well-known pediatrics cardiologists. From March, 2010 he became President of Pediatric Association of Republic of Kosovo. He is Member of European Association of Pediatric Cardiologist; Member of American College of Cardiology; Fellow of American College of Cardiology, New Orelans, USA; Member of Editorial Board of Medical Journal "Medicus", Republic of Macedonia. In March 2011 he was elected as a Director of Pediatric Emergency in Prishtina; in September, 2011 he was elected as a Director of Board for developing Cardiac Surgery Center in Prishtina; and Director of Pediatric School of Kosovo Pediatric Association. Dr Ramush has been elected as a member of editorial board in many world known Medical Journals. Dr Ramush is the author of more than 62 scientific articles published in different indexed and with impact factor journals.

Fields of interest are: Prenatal and postnatal diagnosis and treatment of congenital heart disease

ADVANCES IN THE TREATMENT OF THE FAMILIAL HYPERCHOLESTEROLEMIA - CASE REPORT

Ramush Bejiqi[1,1,2,3], A. Maloku[1], A. Mustafa[1], A. Keka[1], R. Bejiqi[1]
[1]Department of Pediatrics Cardiology, Pediatric Clinic, UCC of Kosovo, Republic of Kosovo
[2]Medical School, University of Gjakova, Gjakove, Kosovo
[3]Texas Health Science Center, San Antonio, Tx, USA

Homozygous autosomal dominant hypercholesterolaemia (hoADH), an orphan disease caused by mutations in low-density lipoprotein receptor (LDLR), apolipoprotein B (APOB), or proprotein convertase subtilisin-kexin type 9 (PCSK9), is characterized by elevated plasma low-density lipoprotein-cholesterol (LDL-C) levels and high risk for premature cardiovascular disease (CVD). The exact prevalence of molecularly defined hoADH is unknown. Conventional lipid-lowering treatments are modestly effective. Evolocumab, a fully human monoclonal antibody that inhibits proprotein convertase subtilisin/kexin type 9 (PCSK9), reduced LDL cholesterol by more than 20 % in a lot of published studies. Pediatric patients with homozygous familial hypercholesterolemia (HoFH) have an increased risk of atherosclerotic cardiovascular disease and difficulty meeting low-density lipoprotein cholesterol (LDL-C) goals. Here we present a boy from Kosovo diagnosed and treated by conventional lipid-lowering medicaments and in one year we added Evolocumab and early results of combined therapy.

The aim of presentation was to provide short-term safety and efficacy data for Evolocumab in patients with homozygous FH (HoFH) hypercholesterolemia

We present recorded data in diagnosis, treatment and assessment of young boy with HoFH.

A 17-year-old boy, previously diagnosed with HoFH despite aggressive conventional lipid-lowering therapy continued with high level of hypercholesterolemia and LDL-C. In cooperation with Ministry of Health and Association for Rare Disease of Kosovo we managed to secure medicament Evolocumab and after completing clinical and cardiological evaluation (echocardiography of the carotid arteries with Doppler and color Doppler, coronarography) we started with additional treatment - Evolocumab. Initial dose of Evolocumab was 5mg daily and after three months level of hypercholesterolemia and LDL-C rapidly decreased: total cholesterol from 17.59 mmol/l on 7.03 mmol/l and LDL from 14.9 mmol/l on 6.25 mmol/l. During this period of treatment xanthomas didn't manifest signs of growth and no new xanthoma was registered.

This case report shows that Evolocumab was well tolerated and in addition to conventional therapy effectively reduced plasma LDL-C levels in patients with HoFH. This short experience and recent publications give us enough courage to start treating children with heterozygous hypercholesterolemia resistant in conventional lipid lowering therapy.

Keywords: Autosomal dominant hypercholesterolemia, Familial homozygous hypercholesterolaemia, LDL cholesterol, Evolocumab.

René Santer



René Santer finished Medical School in Munich, Germany, in 1982. Already at that time, he was specializing in Pediatric Metabolic Medicine (PMM) and wrote his MD thesis on "Characterization of alkaline phosphatase isoenzymes and prenatal diagnosis of hypophosphatasia". He completed his pediatric training at the Department of Pediatrics in Kiel, Germany, followed by a 3-year fellowship in Pediatric Gastroenterology in Buffalo, New York, USA. After 'Habilitation' with a thesis on the relationsship of inflammatory mediators and essential fatty acid status, he was appointed Associated Professor in the Department of Pediatrics of the University of Hamburg, Germany, in 2004, and promoted to Full Professor of Pediatrics in 2006.

Prof. Santer's field of work is Inborn Errors of Metabolism (IEM), and early on he established a metabolic and genetic laboratory working in this area. He is particularly interested in inborn errors of carbohydrate metabolism, and here especially in glucose transporters. Various genetic defects in this area have first been described by Prof. Santer. He has published more than 300 original papers listed in PubMed and is also the author of numerous book chapters on carbohydrate metabolism. He is a long-standing member and lecturer of the European Society for the Study of Inborn Errors of Metabolism (SSIEM) and was President of the corresponding German society (APS/GfAS) for more than 10 years.

Since his retirement in 2024, Prof. Santer has continued to be active as a senior advisor and research associate at the Institute of Human Genetics at the Technical University of Munich, among others.

NEW DEVELOPMENTS IN HEPATITIC GLYCOGEN STORAGE DISORDERS

René Santer
Dept of Pediatrics, University Medical Center Eppendorf, Hamburg, Germany
Inst of Human Genetics, Technical University Munich, Helmholtz Center Munich, Munich, Germany

Hepatic glycogen storage diseases (with its subtypes GSD Ia and Ib, GSD III, GSD VI and IX, and the Fanconi-Bickel syndrome, FBS) due to defects in the glucose-6-phosphatase system, the glycogen debanching enzyme, the liver phosphorylase system, or the glucose-transporter-2, respectively, are all rare hereditary disorders of carbohydrate metabolism. Although their severity differs, the typical manifestation common to all subtypes is a combination of hepatomegaly and hypoglycemia. In general, treatment is symptomatic with the aim to stabilize glucose homeostasis. This can be accomplished by frequent feeds, continuous nasogastric drip feeding of glucose polymers, or the intake of uncooked modified corn starch.

New developments in the treatment of these GSDs will be presented. These include the increased use of continous glucose monitoring which is more and more accepted by patients and physicians.The use of SGLT2 inhibitors (gliflozins) for the very succesful treatment of neutropenia in GSD Ib as well as the tubulopathy in FBS will be presented along with the different underlying pathogenetic mechanisms. The role of liver transplantation in GSD Ia, Ib and III will also be discussed, although the decision to use this approach has not become any easier in view of the future possibility of treating these disorders by various forms of gene therapy. First results of the ongoing AAV8-based phase III gene therapy trial in GSD Ia as well as preclinical developments in RNA-based treatment and genome editing will be presented.

Keywords: Glycogen storage diseases, Hypoglycemia, Hepatomegaly, Glucose homeostasis, Gene therapy.

DE NOVO GAIN-OF-FUNCTION VARIANTS IN CLCN7 CAUSE HYPOPIGMENTATION AND LYSOSOMAL STORAGE DISEASE

René Santer
Dept of Pediatrics, University Medical Center Eppendorf, Hamburg, Germany
Inst of Human Genetics, Technical University Munich, Helmholtz Center Munich, Munich, Germany

An acidic pH is maintained within lysosomes by an ATP-driven proton pump and the Cl^-/H^+ antiporter ClC-7 encoded by CLCN7. Homozygous loss-of-function in CLCN7 or its obligate β-subunit OSTM1 lead to osteopetrosis and most CLCN7 heterozygotes also show (milder) osteopetrosis. Recently, two patients heterozygous for CLCN7 p.Y715C were reported without osteopetrosis but a novel phenotype of hypopigmentation, organomegaly, and delayed myelination and development ("HOD"). [1]

We present two more HOD-patients together with results of morphologic and electrophysiologic studies.[2] Pt 3, a blond boy now 6 y old, presented with massively enlarged abdominal organs (with fully preserved function) due to generalized histiocytic storage of foamy material, vacuolated leukocytes and elevated chitotriosidase. Numerous in vitro enzymatic studies yielded normal results. Brain volume reduction and delayed myelination were seen on cMRI. The clinical course is progressive (despite chloroquine treatment known to increase lysosomal pH) and characterized by massive thickening of bowel walls causing chronically impaired intestinal transit. Trio exome analysis showed heterozygosity for the novel CLCN7 de novo variant p.K285T. In pt 4, a boy with similar clinical picture who had died years ago at age 15 months without diagnosis, heterozygosity for p.Y715C was now found.

K285T less than Y715C showed increased current amplitudes at cytoplasmic-positive poten-tials. Voltage dependencies appeared shifted towards less positive potentials with a dominant effect on the ClC-7 dimer. Both variants, located in spatial vicinity to a PI(3,5)P2 binding site, showed a different degree of decreased ClC-7 inhibition by PI(3,5)P2 and further shifted voltage-dependent gating to less positive potentials. K285T and Y715C cause lysosomal hyperacidification in patient fibroblasts and differently enlarged vacuoles in cells and tissues.

CLCN7 variants lead to different phenotypes, which in turn can also vary in their severity.

Keywords: CLCN7, Osteopetrosis, Lysosomal hyperacidification, Hypopigmentation.

Ruzica Kravljanac



Prof. Ružica Kravljanac, MD, PhD, is the Head of the Department of Pediatric Neurology at the Institute for Mother and Child Healthcare of Serbia and a Professor of Pediatrics at the University of Belgrade Faculty of Medicine. She completed her medical degree, pediatric specialization, fellowship in Clinical Neurophysiology and Epileptology, master's thesis, and PhD all at the University of Belgrade. She has also trained internationally as a visiting fellow and clinician at prestigious institutions, including Mt. Sinai Hospital and NYU Comprehensive Epilepsy Center in New York, the National Neurological Institute Carlo Besta in Milan, and Massachusetts General Hospital at Harvard Medical School.

Professor Kravljanac has authored 117 scientific articles, with an h-index of 15 and 798 citations, reflecting her contributions to pediatric neurology, clinical neurophysiology, and epilepsy research. Her work has advanced the understanding and treatment of neurological disorders in children, combining clinical expertise with research excellence and international collaboration.

DIAGNOSTIC PATHWAYS OF NEUROPROGRESSIVE DISEASE - INSIGHTS FROM CLN2 PATIENTS

Ružica Kravljanac
Institute for Mother and Child Healthcare of Serbia, Faculty of Medicine University of Belgrade, Serbia

Neuronal ceroid lipofuscinosis (NCL) is the most frequent neurodegenerative disorders in children including 14 different subtypes of disease. There is a significant difference between subtypes in their presenting symptoms and clinical, imaging, and electrophysiological findings. NCL is a leading etiology of childhood dementia characterized by neuronal death due to lysosomal accumulation of autofluorescent storage material (ceroid lipofuscin) in neurons. In our region, the most frequent type of NCL is CLN2. The incidence of CLN2 is <0.5 per 100 000 live births presenting the most common etiology among the patients with progressive myoclonus epilepsy. CLN2 disease is caused by deficiency of the tripeptidyl peptidase 1 (TPP1) enzyme due to mutations in the TPP1 gene. Seizures are one of the most common presenting symptoms, although patients may also present with language deficits, movement disorders and behavioral issues. Diagnostic pathway of CLN2 will be present summerizing literature data and clinical expirience in 23 patients treated in our center. Early diagnosis is essential, since enzime replasment treatment given at early stage of disease might suppress fast neurological progression in CLN2 cases.

Keywords: Neuronal ceroid lipofuscinosis, CLN2, Tripeptidyl peptidase 1, Childhood neurodegeneration.

Sonja Bojadzieva



Prof. Dr. Sonja Bojadzieva was born in Skopje, Macedonia. She finished Secondary medical education in Medical School Center D-r."Pance Karagjozov ", and Faculty of Medicine at "St. Cyril and Methodius" University –in Skopje. In 2001 she finished Pediatrics specialization, 2003 postgraduate studies MSc "Significance of quantitative determination of albumin and IgG in the liquor in differentiation of various conditions in the central nervous system, 2013 she finished doctorate PhD "Correlation between genotypic, phenotypic and immunological characteristics of inflammatory bowel disease". In 2015 became Pediatric Gastroenterohepatology Subspecialisation. From 1996 she works at the University Children's Hospiatal Skopje, and from 2015 as a chief of the Department of Gastroenterology From 2001 she is a Head of Department of Pediatrics. She is the part of many projects, Scientific and Research Works and active participation at congresses and meetings national and internationals. She is full member in ESPGHAN.

PROGRESSIVE FAMILIAR INTRAHEPATIC CHOLESTASIS – NEW TREATMENT OPTION

Sonja Bojadzieva
Department of Pediatric Gastroenterohepatology, University Children's Hospital, Skopje, North Macedonia

Progressive Familial Intrahepatic Cholestasis (PFIC) represents a group of rare autosomal recessive liver disorders characterized by defective bile formation and progressive cholestasis. Affected children typically present in infancy or early childhood with intractable pruritus, jaundice, growth failure, fat-soluble vitamin deficiency, and progression to cirrhosis and end-stage liver disease. Historically, management options have been limited to symptomatic relief, nutritional support, surgical biliary diversion, and ultimately liver transplantation. While transplantation remains curative, it carries lifelong risks, underscoring the urgent need for disease-modifying therapies.

Recent advances in understanding bile acid metabolism have led to the development of ileal bile acid transporter (IBAT) inhibitors as a novel therapeutic strategy. Maralixibat, an oral, once-daily IBAT inhibitor, reduces enterohepatic circulation of bile acids, thereby lowering systemic bile acid levels. Clinical trials in children with PFIC type 2 have demonstrated significant reductions in serum bile acids, accompanied by meaningful improvements in pruritus, sleep quality, and quality of life. Furthermore, some patients achieved normalization or stabilization of liver biochemistry, suggesting potential disease-modifying effects. Importantly, Maralixibat has shown a favorable safety profile, with the most common adverse events being mild gastrointestinal symptoms.

The introduction of Maralixibat marks a paradigm shift in the treatment of PFIC, offering a non-surgical and potentially liver-sparing option. Ongoing studies aim to expand its indication to other PFIC subtypes and evaluate long-term outcomes, including progression to transplantation. For pediatric patients and their families, Maralixibat provides new hope for improved symptom control, growth, and preservation of native liver function.

Keywords: Progressive familial intrahepatic cholestasis (PFIC), Maralixibat, IBAT Inhibitor, Pediatric cholestasis, New therapies.

Susan Gear



Susie's passion is using her 30 years' experience in international business to facilitate innovative international collaborations between people living with rare kidney diseases, clinicians, laboratory scientists, and pharmaceutical companies. One example of these is the Alport Syndrome Alliance – a global network advancing treatments and knowledge to create a brighter future for those living with Alport Syndrome. At the Alliance's 9th international workshop in Beijing (September 2025), there were updates on nine exciting ideas for treatments delivering positive results in pre-clinical studies and nine ongoing clinical trials in Alport Syndrome. In 2023 Susie was shortlisted for the UK's 'Woman of the Year'. Susie was on the UK's NHS England Rare Diseases Advisory Group and contributes to many international publications on Alport Syndrome including Women and Girls with Alport Syndrome, the recent ERKNet and ERA Guidelines for the diagnosis and management of Alport Syndrome. Susie also co-ordinates international projects to promote the need for countries to provide genetic testing to diagnose people with rare kidney disease early and guidelines for the diagnosis and management of Alport Syndrome in resource-constrained environments. Susie's mother was diagnosed with Alport Syndrome over 50 years ago and it impacts many members of the family.

REPORT FROM THE BEIJING ALPORT MEETING

Susan Gear
Alport UK, Oxford, United Kingdom

The 2025 International Workshop on Alport Syndrome, held in Beijing from 5–7 September 2025 (preceded by a patient meeting on 4 September), represented a pivotal forum where stakeholders from across the world gathered to advance understanding, diagnosis, treatment, and patient-care strategies for Alport syndrome. Organized by the Alport Syndrome Alliance in collaboration with Alport UK, Peking University First Hospital, the Chinese Alport Syndrome Parent Association, and the IPNA Training Center (China), the workshop delivered an integrated program that engaged patients, clinicians, scientists, geneticists, and industry partners.

The workshop highlighted the latest research in renal pathology, hearing and ophthalmologic manifestations, genetic diagnostics, and mutation spectrum. Updates from international patient registries and clinical trials were presented, alongside assessments of both established and emerging therapeutic approaches. Particular emphasis was placed on strengthening connections between young adult patients, caregivers, and experts, ensuring that patient perspectives and lived experiences informed future research directions and treatment access.

Special sessions addressed regulatory and pharmaceutical advances, including updates from the Phase 2 ALPESTRIA-1 clinical study with Vonafexor. In addition, initiatives related to patient registries, biobanks, and health policy underscored efforts to build sustainable infrastructures for diagnosis, monitoring, and international collaboration.

By fostering cross-disciplinary exchange and aligning global efforts, the 2025 workshop successfully accelerated dialogue around discovery and therapy development, while also advancing strategies to improve quality of life and outcomes for individuals living with Alport syndrome worldwide.

Keywords: Alport syndrome, Workshop, Beijing.

Tatjana Milenkovic



Dr. Tatjana Milenkovic, MD, PhD, is an attending pediatric endocrinologist at the Mother and Child Health Care Institute of Serbia "Dr Vukan Cupic" in Belgrade. She graduated from the School of Medicine, University of Belgrade, in 1985 and completed her residency in pediatrics at the same institution. Dr. Milenkovic earned her Master's degree in clinical endocrinology in 2001, focusing on congenital hypothyroidism, and received her PhD in 2008, studying endocrine disorders in children and adolescents after bone marrow transplantation.

She has actively participated in numerous international training programs, including ESPE Winter and Summer Schools, and has extensive experience in pediatric endocrinology, growth disorders, diabetes, congenital adrenal hyperplasia, and neonatal screening. Over her career, she has authored and co-authored more than 50 scientific publications in both national and international journals and has contributed to multiple congresses and registries in pediatric endocrinology.

Dr. Milenkovic is a member of several professional organizations, including the European Society for Paediatric Endocrinology (ESPE), the International Society for Pediatric and Adolescent Diabetes (ISPAD), and the Serbian Medical Chamber. Her work has significantly advanced pediatric endocrinology in Serbia and the region, combining clinical practice, research, and education.

EARLY ONSET OF SEVERE OBESITY: WHAT COULD IT BE?

Tatjana Milenkovic
Institute for Mother and Child Healthcare of Serbia, Faculty of Medicine University of Belgrade, Serbia

Obesity caused by a mutation in one gene is very rare, most often autosomal recessive diseases. They are characterized by extreme obesity with a body mass index of ≥35 kg/m2, and are manifested already in the first years of life. Obesity occurs due to hyperphagia, which is defined as pathological hunger and preoccupation with food, with an almost absent feeling of satiety. Disorders are caused by leptin deficiency, leptin receptor, proopiomelanocortin (POMC) deficiency, proopiomelanocortin-degrading enzyme deficiency - PCSK, as well as mutations in the melanocortin 4 receptor (MC4R) gene. Syndromes such as Bardet-Biedl and Alström present as leptin receptor deficiency because in these diseases the leptin receptor cilia cannot reach the the surface of POMC neurons.

In addition to extreme obesity, these children almost always have associated health disorders that can be life-threatening, such as cortisol deficit. Thus, children with POMC deficiency have decreased ACTH and cortisol and consequent hypoglycemia. Children with PCSK deficiency may have primary hypothyroidism, hypocorticism, hyperinsulinemic hypoglycemia, metabolic acidosis, polyuria, polydipsia, and diabetes mellitus. Since leptin plays a very important role in many systems of our body, deficiency of leptin and leptin receptors leads to secondary hypothyroidism, frequent infections, hyperinsulinism, stunted growth, hypogonadotropic hypogonadism and delayed puberty.

Since these are very serious diseases that require early diagnosis, not only to stop obesity, but also to treat numerous associated health disorders, today it is considered mandatory that all children under the age of 5 who have a body mass index ≥35 kg/m2 undergo genetic testing. Monogenic obesity should also be considered in older children with obesity who have a history of being extremely obese since early childhood.

In Serbia, genetic testing test can be done at the Institute for Molecular Genetics and Genetic Engineering in Belgrade and it is free of charge. After diagnosis, leptin therapy is mandatory if it is a question of leptin deficiency. All other disorders should be treated with setmelanotide, a drug that directly acts on the melanocortin 4 receptor.

Keywords: Monogenic obesity, Leptin-melanocortin pathway, Hyperphagia.

Todor Arsov



Dr. Todor Arsov, born in Skopje, where he completed medical studies and received a MS degree in molecular medicine in the area of human genetics – inherited thrombophilia, Todor holds a PhD in genetics from the Australian National University, where he held a position of a Senior Research Fellow at the Centre for Personalised Immunology. Following two postdoctoral positions at Stanford University and The University of Melbourne where he started a new molecular genetics laboratory, he furthered his qualifications by completing professional MS studies in genetic counselling (Sydney University) and diagnostic genomics (Queensland University of Technology) and specialty training in clinical genetics (Medical School in Skopje). His research interests are in the area of rare monogenic genetics, particularly in the areas of immunology, neurology, cardiology and metabolic conditions, as well as the ethics of genomic testing. Currently, Todor is a professor of Genetics Faculty of Medical Sciences at the University Goce Delcev in Shtip and is a visiting scientist at the Francis Crick Institute in London, UK.

GENETIC COUNSELLING ISSUES IN ALPORT SYNDROME

Todor Arsov
Faculty of Medical Sciences, Goce Delcev University, Stip, Macedonia

Traditionally, Alport syndrome (AS) described a childhood-onset X-linked kidney failure, often accompanied by reduced hearing and/or eye problems, caused by pathogenic *COL4A5* variation. Later, the AS spectrum included patients of both sexes with similar presentations and biallelic *COL4A3/COL4A4* pathogenic variants (autosomal recessive AS). Recently, it has been recognised that heterozygotes for some *COL4A3/COL4A4* pathogenic variants may develop milder later onset kidney disease - sparking the terminology debate (autosomal dominant AS v. thin membrane nephropathy, or collagen 4 related nephropathy). Variants of uncertain significance (VUS) pose a great challenge in genetic counselling for AS: they may, *or may not*, explain the clinical situation and resolving the uncertainty requires time (finding additional patients with the same variant), and/or conducting expensive and not readily available functional tests. Additional challenges are posed by the secondary and incidental findings - significant genetic findings which are not related to the primary condition.

This presentation will discuss a few challenging clinical cases related to these issues from the perspective of a healthcare system without a formal genetic counselling (or clinical genetics) services and in the context of genomic testing and the evolving guidelines for considering otherwise healthy AS carrier as potential kidney donors for their relatives. Mirroring the evolution of genomic testing and the clinical understanding of the condition, genetic counselling for AS includes education about all forms of Mendelian inheritance, including “de novo” genetic mechanisms, discussions about predictive testing of seemingly asymptomatic adults in the family, counselling about incidental/secondary findings and about uncertainty linked with VUS-es, the variable clinical expressivity and the reduced penetrance.

Keywords: Alport syndrome, Genetic counseling, Variants of uncertain significance.

RARE GENETICS AND VARIANT INTERPRETATION: JUDGING A GENE

Todor Arsov
Faculty of Medical Sciences, Goce Delcev University, Stip, North Macedonia
Francis Crick Institute, London, UK
MENDEL, Centre for Genetic Education, Skopje, North Macedonia

The interpretation of genetic variants remains one of the most challenging issues in medical genetics, despite the interpretation guidelines put forward by the learned genetic and scientific societies. Although with experience and more extensive genetic testing variant interpretation became more uniform across laboratories, there still exist significant problems of conflicting interpretations of genetic variants in the context of the inherent genetic uncertainty associated with the variants of uncertain significance and genes of uncertain significance (genes of uncertain association with a specific clinical phenotype). This is particularly true in the world of the rare and especially ultra-rare diseases where we often encounter the situation of a genetic variant "never seen before" - an inherited or 'de novo' private genetic variant in a gene associated with the relevant phenotype: the variant is absent from both the clinical and population databases, there is no (clinically validated) functional test or the test is not readily available (of note, inequality in access to genetic/genomic services means more than just access to affordable sequencing machines/technologies, and includes access to functional tests, genetic counselling etc…). These variants of uncertain significance may be de novo, which (sometimes) help with the variant interpretation, but are sometimes inherited from an unaffected non-penetrant parent, leading to challenges with the variant interpretation. Another dimension of the variant interpretation challenge is the level of certainty required in the particular context, for example is the context clinical, in terms of establishing a diagnosis and affording reproductive options, or is the context a legal/criminal proceeding, where the legal system judges the probability of a criminal as opposed to a natural explanation of what may have happened in a particular case (often involving with recurrent sudden unexplained death, shaken baby syndrome or brittle bone disease). This talk will review some of the challenges of variant interpretation through illustrative cases from in the clinical and legal context.

Keywords: Genetic variant interpretation, Rare and ultra-rare diseases, Clinical vs. Legal Contexts.

Tulay Guran



Dr. Tulay Guran is Professor for Pediatric Endocrinology and Diabetology at Marmara University, School of Medicine, in Istanbul. She was trained in Pediatrics and Pediatric Endocrinology and Diabetology in Istanbul, Turkey, and in molecular endocrinology as a postdoctoral fellow at the University of Birmingham, UK, where she started her research career in the field of rare disorders or steroidogenesis.

Her research group at Marmara University studies rare causes of CAH, non-CAH primary adrenal insufficiency and disorders/differences of sex development. She participates in several national and international commissions (e.g. the European Society Pediatric Endocrinology ESPE, I-DSD, I-CAH) and research projects. She was a former coordinator or ESPE disorders/differences of sex development working group. She is in the steering committee of ESPE Winter School. She holds a member position in the Scientific Advisory Board of Turkish Ministry of Health Neonatal Congenital Adrenal Hyperplasia screening program.

Honors received: 2015 Young Investigator Award of ESPE.

NOVEL RARE FORMS OF DIFFERENCES OF SEX DEVELOPMENT

Tulay Guran

Marmara University, School of Medicine, Department of Pediatric Endocrinology and Diabetes, Istanbul, Turkey

Differences in Sex Development (DSD) are a group of rare congenital conditions where the typical development of chromosomes, gonads, or genital anatomy is altered. These variations may involve differences in chromosomal patterns (such as 45,X or 47,XXY), gonadal development (testes, ovaries, or ovotestes), or external/internal reproductive anatomy. Some individuals with DSD are identified at birth due to atypical genital appearance, while others may be diagnosed later in life because of delayed puberty, infertility, or incidental genetic findings.

Management of DSD requires an initial workup that includes clinical, biochemical, and genetic investigations to guide diagnosis. The clinical evaluation includes a thorough history (maternal drug use, family history of DSD, unexplained neonatal deaths) and physical examination (including anogenital measurements). Urgent investigations should rule out life-threatening adrenal insufficiency in cases of suspected congenital adrenal hyperplasia, requiring immediate glucocorticoid and mineralocorticoid therapy. Biochemical tests include measurement of sex steroids, adrenal hormones, gonadotropins, and anti-Müllerian hormone (AMH) to assess gonadal function. Genetic testing, including karyotyping and next-generation sequencing panels, helps determine the molecular diagnosis, guiding management decisions.

In this symposium, recently described forms of DSD will be discussed together with some clinical cases.

Keywords: Differences in sex development, Chromosomal and gonadal variations, Genetic testing.

Urh Groselj



Prof. Urh Groselj, PhD, MD, MA, graduated (2007) and received his PhD (2012) from the Faculty of Medicine, University of Ljubljana, and his MA (2008, summa cum laude) from the Faculty of Medicine, University of Leuven, Belgium. Since 2014, he has been a specialist paediatrician at the Department of Endocrinology, Diabetes and Metabolism, University Children's Hospital – UMC Ljubljana. Since 2022, he has been an Associate Professor of Paediatrics and Assistant Professor of Medical Ethics, and a member of both Departments at the Faculty of Medicine of the University of Ljubljana. He was a Fulbright Scholar, and a Visiting Scholar (Asst. Prof.) at School of Medicine, Stanford University, California, USA. Since 2013, he has been a member of the National Medical Ethics Committee of Slovenia. Since 2024, he has been the Vice President of the Slovenian Heart Foundation. His clinical and research interests are in rare diseases, especially metabolic diseases, familial hypercholesterolaemia, rare dyslipidaemias, newborn and paediatric screening, clinical genomics, and medical ethics. Prof. Groselj manages the clinical part of the newborn screening programme (including the planned expansion of the programme in 2024), as well as the national programme of universal screening for familial hypercholesterolaemia, including the programme of modern NGS diagnostics for dyslipidaemia at the UMC Ljubljana. He coordinated the preparation of the national registry of rare non-malignant diseases of the Republic of Slovenia and leads the ELSI part of the Slovenian Reference Genome Project. He is a member of the scientific committee of FH Europe, a member of EndoERN and from 2024 a lead representative of MetabERN for Slovenia. From 2025, Prof. Groselj is leading Genomics Committee of the International Society of Neonatal Screening (ISNS).

NEWBORN SCREENING FOR RARE DISEASES IN THE GENOMICS ERA

Urh Groselj
University Children's Hospital – UMC Ljubljana

Newborn screening (NBS) has long been a cornerstone of public health, originally developed to detect a limited number of congenital disorders such as phenylketonuria and congenital hypothyroidism. Early identification and treatment have consistently prevented severe and irreversible outcomes. With the advent of genomic technologies, NBS is now broadening to include a wider spectrum of rare diseases (RDs).

This expansion brings major opportunities for earlier diagnosis and targeted interventions, while also presenting significant challenges for clinical implementation, ethics, and health system capacity. The evolution of NBS from its biochemical origins to the integration of genomic methods such as next-generation sequencing and whole-exome sequencing illustrates the expanding potential of early detection. Incorporating RDs into screening panels raises complex issues, including condition selection, validation of novel technologies, confirmatory testing, and the need for comprehensive long-term follow-up. At the same time, the shift highlights the tension between population-wide public health principles and the individualized paradigm of rare disease care. Ethical considerations and international harmonization of policies are essential to ensure equitable and sustainable access to genomic NBS. Expanding NBS to rare diseases offers the potential to transform early diagnosis, reduce diagnostic odysseys, and improve outcomes through timely, precise interventions. To achieve this, programs must establish robust, evidence-based inclusion criteria, validated diagnostic pathways, and durable follow-up structures. The rapid development of genomic technologies further requires advanced data infrastructures and international collaboration, ensuring responsible and equitable implementation. As NBS enters the genomics era, its future success will depend on balancing broad public health impact with personalized, patient-centered care. The picture is attached, while the short bio is below.

Keywords: Newborn screeening, Genomic techonologies, Rare diseases.

Velibor Tasic



Prof. Velibor Tasic graduated from the Medical School in Skopje in 1980 and began working at the Clinic for Children's Diseases the same year. He specialized in pediatrics in 1986 and pursued extensive training in pediatric nephrology in Belgrade, London, Birmingham, and Hannover between 1986 and 2001. He completed her PhD in 1997 at the University "Sv. Kiril i Metodij" in Skopje, focusing on the clinical, biological, and prognostic aspects of acute post-streptococcal glomerulonephritis in children. He currently holds the academic rank of Full Professor of Pediatrics and Pediatric Nephrology at the Medical School in Skopje.

Professor Velibor Tasic is an active member of multiple international and regional societies, including the International Pediatric Nephrology Association, European Society for Pediatric Nephrology, EDTA-ERA, and the European Academy of Pediatrics, as well as the Macedonian Pediatric Association. He has contributed to several working groups focused on pediatric nephrology and rare kidney disorders and has served in leadership roles including Secretary General of the Macedonian Pediatric Association (2004–2006) and Council Member of the European Society of Pediatric Nephrology (2009–2012).

He has organized and chaired numerous regional and international conferences, including the SEPNWG Teaching Courses, Balkan Alport Meetings, and Rare Disease Conferences in Skopje. He has been invited as a lecturer at teaching courses and pediatric schools across Europe. Professor Velibor Tasic has authored over 200 PubMed-indexed publications and presented approximately 400 conference papers and abstracts, making significant contributions to the field of pediatric nephrology and rare kidney diseases.

REPORT ON THE SURVEY OF DIAGNOSTIC AND TREATMENT CHALLENGES FOR PRIMARY HYPEROXALURIA IN SOUTH EASTERN EUROPE

Velibor Tasic
University Children's Hospital, Skopje, North Macedonia

Primary hyperoxaluria (PH) is a group of rare hereditary diseases affecting hepatic glyoxylate metabolism, resulting in excessive oxalate production, nephrolithiasis, nephrocalcinosis, renal failure and systemic oxalosis. Due to limited information available regarding diagnostic challenges and therapeutic options for PH in the countries of Southeast Europe we aimed to analyze current data from this area.

An online questionnaire was distributed to the presidents of national pediatric nephrology associations or senior pediatric nephrology consultants experienced in management PH located in Southeastern Europe. The questionnaire contained five sections (i) Country demographics and PH education on graduate/postgraduate level (ii) Facilities related to biochemical diagnosis (iii) Facilities related to genetic diagnosis (iv) Novel therapeutic possibilities (especially modern RNA interference therapy) (v) Comments regarding the achievements and weaknesses related to PH management.

Data were collected from all 11 countries located in Southeastern Europe. The number of medical faculties ranges from 1 (Kosovo and Montenegro) to 128 (Turkey) and pediatric nephrology departments from 1 (Kosovo, Montenegro, North Macedonia) to 70 (Turkey). PH is not part of the undergraduate and postgraduate curriculum in Serbia, Croatia, Romania and Albania. Measurement of u-oxalate is not available in 4 non-EU countries (Albania, Macedonia, Kosovo, and Bosnia&Herzegovina) and in one EU country (Bulgaria). U-glycolates and u-glycerates are determined only in Croatia, Romania and Greece. HOGA is not determined in the Southeast Europe. Determination of plasma oxalate is available only in Croatia. Facilities for genetic testing PH are available in majority of countries. Montenegro, Kosovo and Bosnia&Herzegovina send for genetic testing abroad. Minimally invasive surgery is available in most countries, except in three non-EU countries (Albania, Macedonia, Bosnia&Herzegovina). Kidney-liver transplantation is available in Croatia, Turkey and Greece. RNA interference therapy is possible in most countries of Southeast Europe, except in two non-EU countries (Albania, Bosnia& Herzegovina).

This SEPNWG study showed the diversity in diagnostic and therapeutic possibilities regarding PH in the countries of Southeast Europe. Small samples size limits statistical analysis, but there are obvious differences between EU and non-EU countries. In the latter, the situation is worrisome, because there is a lack of basic screening for illness, which is the determination of oxalate in the urine.

Key words: Primary hyperoxaluria, Oxalate, Survey, Diagnosis, Genetics.

Yaacov Frishberg



Yaacov Frishberg was born in Israel and graduated from the Faculty of Medicine at The Hebrew University of Jerusalem. Following a pediatric residency at Beilinson Medical Center in Petah-Tikva, He completed a fellowship in Pediatric Nephrology at the Children's Hospital of Philadelphia, USA, where he conducted research in molecular renal immunology.

Upon returning to Israel, Yaacov Frishberg joined the Division of Pediatric Nephrology at Shaare Zedek Medical Center in Jerusalem. He is currently a Professor of Pediatrics at the Hebrew University of Jerusalem and serves as the Director of the Division of Pediatric Nephrology at Shaare Zedek Medical Center.

Yaacov Frishberg's primary scientific interests focus on hereditary kidney diseases in children, including kidney stone disease—particularly hyperoxalurias—nephrotic syndromes, and mitochondrial cytopathies. Clinically, he specializes in renal replacement therapy in children, encompassing various dialysis modalities and kidney transplantation.

CARING TOGETHER FOR CHILDREN WITH CHRONIC KIDNEY DISEASE

Yaacov Frishberg
Shaare Zedek Medical Center, Jerusalem, Israel

The Z family has three children, all diagnosed with Alport syndrome, each at a different stage of their kidney journey. Their story reflects not only the medical challenges of chronic kidney disease but also the importance of supporting every child's healthy side to help them grow into confident, capable young adults.
To reduce disruption to family life, we established a pediatric nephrology day hospital unit. This unit provides treatments, procedures, and monitoring in an outpatient setting, helping to prevent unnecessary hospitalizations. It also enables us to deliver truly multidisciplinary care, addressing the challenges that arise from the many organ systems affected by kidney disease.

In the hemodialysis unit, attention to the child's well-being extends far beyond the machine. Medical clowns, art therapists, drama therapists, and even animal therapists bring joy and creativity into an environment that could otherwise feel sterile and overwhelming. These interventions open new paths to overcome emotional stress associated with the disease and its demanding treatments.

For adolescents/young adults preparing to move from pediatric to adult care, a transition clinic has been established. Its focus is not only on ensuring medical continuity—such as for kidney transplant recipients—but also on equipping young people with the tools, confidence, and independence they need to manage their health while pursuing studies, careers, and personal goals. This step also acknowledges the needs of parents, actively incorporating their role in the transition process and reassuring them that their children are in safe hands.

Achieving all of this requires a multidisciplinary approach. Physicians, nurses, psychosocial professionals, dietitians, and educators work together alongside families to ensure that each child can thrive in every aspect of life.

Key words: Chronic kidney disease, Day hospital unit, Child's healthy side, Transition clinic, Multidisciplinary approach

NOVEL THERAPEUTIC APPROACHES FOR PRIMARY HYPEROXALURIA

Yaacov Frishberg
Shaare Zedek Medical Center, Jerusalem, Israel

Primary hyperoxaluria type 1 (PH1) is a rare autosomal recessive disorder of endogenous oxalate synthesis caused by deficiency of the liver-specific peroxisomal enzyme alanine:glyoxylate aminotransferase. PH1 results from bi-allelic pathogenic variants in *AGXT*. Oxalate, in humans, is an end-product which cannot be further metabolized. Calcium oxalate crystals are insoluble in body fluids and lead to kidney stones, nephrocalcinosis and progressive kidney failure. The ultimate cure is combined liver-kidney transplantation. This talk will discuss the development of several strategies to treat this disorder. The first approved drug for patients with PH1 was lumasiran, a liver directed RNAi therapeutic targeting HAO1, encoding glycolate oxidase, thus leading to decreased glyoxylate expression. Glyoxylate is the substrate of oxalate. Nedosiran, a liver-directed siRNA targeting LDHA, encoding lactate dehydrogenase the enzyme responsible for the last reaction in oxalate production. This lecture will describe further attempts to treat this disorder such as DNA editing. The potential advantages and hurdles in implementing gene therapy in this context will be discussed.

Keywords: siRNA therapeutic, Lumasiran, Nedosiran, Primary hyperoxaluria type 1, Glycolate oxidase, DNA editing, Gene therapy

Zoran Gucev



Zoran Gucev was born and educated in Skopje North Macedonia. After graduating the Medical School in Skopje, he there completed his residency in pediatrics. Additional education for several years was done at OHSU, Portland OR, USA; UCSF at San Francisco, CA, USA, Vienna, Austria, Paris, France, Belgrade Serbia, Zagreb Croatia. Additional short stays in Murcia, Spain, Berlin and Leipzig in Germany, Utrecht in the Netherlands. Zoran is a member of many national and international professional associations (ESPE, BDS, ZLM…). He authored and co-authored 141 Pubmed articles, some of them in Nature, NEJM…His teaching career spans several decades. He also graduated at the Faculty for philosophy in Skopje. At the present time he is happily working retiree. Reading, writing, hiking and swimming are part of his life.

GENETICS AND RARE DISEASES

Zoran Gucev
Medical Faculty Skopje, North Macedonia
Atelos, Skopje, North Macedonia

Thirty million in USA and 27-36 million EU citizens suffer from a rare disease. Many are never diagnosed. The number of RDs are constantly growing: from 5-7000 only a decade ago, to more than 10000 today. Genetics can discover or confirm well described RDs. However, the diagnosis is complex. Duchenne muscular dystrophy can result from mutation or deletion of at least 79 protein-encoding genes. An additional difficulty was that so far analysis have been done based on the initial draft of the human genome published 25 years ago and based largely on one person's DNA. In 2023 scientists published the first draft of the human pangenome of 94 nearly complete, high quality sequences from both sets of chromosomes from 47 individuals with diverse ancestral backgrounds. Searching a single gene defect which is a cause of RD yields new genes weekly. There are also hundreds of variants of unknown significance awaiting molecular and clinical confirmation of being pathologic genes. Having an accurate diagnosis of RD is important as there are hundreds of clinical trials of gene-editing technologies which are a potential cure for a RD. Some are awaiting FDA approval, including gene editing treatments for Hunter and Wiscott-Aldrich syndromes. Most of those diseases are highly debilitating or deadly. A case for neonatal WES or WGS is therefore well founded. About 30 percent of patients in NICU have a genetic disorder. There are about 450 "clinically actionable conditions". Gene variants that heighten the risk for a disorder but not entirely are also of significance. For example, there are 800 genes associated with autism. It took 13 years to complete the first genome at the cost of $3 billion. Today a whole genome can be interpreted in 48 hours. We are showing some of those difficulties in patients diagnosed and/or treated in our clinic and hospital.

Keywords: Rare diseases, Genetic diagnosis, Gene-editing therapies.

Zvi Laron



Prof. Zvi Laron, MD, PhD is a distinguished pediatric endocrinologist recognized globally for his pioneering contributions to pediatric endocrinology and diabetes. Born in Israel, he graduated from Hadassah Hebrew University Medical School, Jerusalem, in 1952. He completed his pediatric residency at Rambam Hospital, Haifa, and undertook fellowship training at Massachusetts General Hospital, Harvard Medical School, and the Children's Hospital of Pittsburgh, USA.

Professor Laron served as Director of the Institute of Pediatric and Adolescent Endocrinology at Beilinson Medical Center, Tel Aviv University, from 1958 to 1992 and has directed the Endocrinology and Diabetes Research Unit at Schneider Children's Medical Center of Israel since 1993. He was appointed Full Professor of Pediatric Endocrinology at Tel Aviv University in 1971.

A founding member of multiple international societies, including the International Society for Pediatric and Adolescent Diabetes (ISPAD) and the European Society of Pediatric Endocrinology (ESPE), Professor Laron has held leadership positions such as President of ISPAD and ESPE. His research and clinical work have focused on growth hormone disorders, pediatric diabetes, and metabolic diseases.

Professor Laron has received numerous prestigious awards, including the Israel Prize (2009), the Andrea Prader Prize from ESPE, the Paul Langerhans Medal, and the Lifetime Achievement Award from the GH Research Society. He has been awarded multiple honorary doctorates from universities across Europe and is a member of the German National Academy of Sciences Leopoldina.

He has contributed extensively to scientific publishing, founding and editing leading journals and book series in pediatric endocrinology, including Pediatric Endocrinology Reviews and serving on editorial boards of journals such as Nature Reviews Endocrinology. With an h-index of 65, over 877 publications, and more than 19,000 citations, Professor Laron's work has profoundly influenced pediatric endocrinology and diabetes care worldwide.

HISTORY AND MYSTERY OF LARON SYNDROME

Zvi Laron
Endocrinology and Diabetes Research Unit, Schneider Children's Medical Center, Petah Tikva, Israel
Faculty of Medical and Health Sciences, Tel Aviv University, Israel

Discovered in 1958 and first published in 1966, Laron Syndrome (LS) OMIM #262500 (primary GH insensitivity) is a rare recessively inherited disease. It is caused by defects in the GH-receptor gene and is characterized by severe dwarfism, characteristic facial features, obesity, hyperlipidemia including high adiponectin and retarded sexual development. The diagnosis is: high serum GH, low to undetectable IGF-I non-responsive to GH stimulation and or genetic analysis. The only treatment is once daily IGF-I administration. Between 1966 to October 2024, 849 patients have been reported with 113 deletions or mutations in the GH-R gene. An unexpected finding was that homozygous patients with LS (as well as for GH gene deletion) are protected from developing CANCER. The cause is still a mystery. Its disclosure is our present project.

To enable tissue studies, mouse and pig models of GH-R KO have been made.

Keywords: Laron Syndrome, GH insensitivity, IGF-I.

Oral Presentations and Case Reports

NEWLY DIAGNOSED ALPORT SYNDROME IN A 5-YEAR-OLD-BOY WITH UNILATERL RIGHT RENAL AGENESIS

Ana Leshnikovska[1], Tamara Stamenkovska Gjorgievska[1], Nora Abazi Emini[1], Julija Gjorgievska[1]
[1]University Children's Clinic, Faculty of Medicine, University "Ss. Cyril and Methodius," Skopje, RN Macedonia

Introduction: Alport syndrome is a hereditary disorder that primarily affects renal function and is frequently associated with sensorineural hearing loss and ocular abnormalities. It results from mutations in genes encoding type IV collagen, an essential component of the basement membranes in the kidneys, cochlea, and eyes. These genetic alterations lead to progressive renal impairment, often culminating in end-stage renal disease.

Objectives: To present a case of genetically confirmed Alport syndrome in a pediatric patient with unilateral right renal agenesis, emphasizing the role of family history and genetic evaluation in diagnosis.

Materials and Methods: We retrospectively analyzed the case of a 5-year-old boy with congenital unilateral right renal agenesis and grade II hydronephrosis of the left kidney. At age 3, he developed a urinary tract infection, and at age 4, he experienced an episode of post-streptococcal glomerulonephritis.

Results: Following this episode, the patient developed persistent microscopic and macroscopic hematuria as well as proteinuria. A positive family history of Alport syndrome on the maternal side—including his mother with microscopic hematuria and his cousin with Alport syndrome—prompted further genetic evaluation. Genetic testing confirmed the presence of a pathogenic variant (c.892-2A>G) in the *COL4A5* gene in hemizygous form in both the patient and his brother, consistent with X-linked Alport syndrome. He remains in good general condition and is receiving renoprotective therapy with an ACE inhibitor (ramipril), which has effectively reduced proteinuria.

Conclusion: This case highlights that, with timely diagnosis and comprehensive management—including genetic testing, regular monitoring, and appropriate pharmacologic therapy—patients with Alport syndrome can maintain a good quality of life, despite the condition's rarity and potential severity. Thorough physical examinations and detailed family history are essential during each clinical evaluation to facilitate early detection of hereditary and potentially life-threatening conditions.

Keywords: Alport syndrome, COL4A5 mutation, Unilateral renal agenesis, Hydronephrosis, Hematuria.

ADOLESCENT WITH PUBERTAL-ONSET VIRILIZATION

Dimitrije Cvetkovic[1], Tatjana Milenkovic[1], Slađana Todorovic[1], Katarina Mitrovic[1,2], Rade Vukovic[1,2] Sanja Panic Zaric[1],
[1]Mother and Child Healthcare Institute of Serbia "Dr Vukan Cupic", Belgrade, Serbia
[2]Faculty of Medicine, University of Belgrade, Belgrade, Serbia.

Background: Disorders of sex development (DSD) present with a wide spectrum of clinical features, ranging from atypical genitalia at birth to delayed or discordant pubertal development. Among 46, XY individuals, 17β-hydroxysteroid dehydrogenase type 3 (17β-HSD3) deficiency is a rare autosomal recessive condition that may remain undiagnosed until adolescence. We describe a case of pubertal-onset virilization in a phenotypic female, ultimately confirmed as 17β-HSD3 deficiency.

Case Presentation: A 17-year-old individual, raised as female, presented with tall stature (180 cm), broad shoulders, absence of breast development, normal pubic and axillary hair, and marked clitoromegaly (>4 cm). Laboratory evaluation showed elevated gonadotropins (FSH 30 IU/L, LH 42 IU/L), estradiol 89 pmol/L (assay-specific), and androgen markers in the male reference range, including inhibin B (219 pg/mL) and AMH (22.4 ng/mL). DHEAS was midly elevated (506 µg/dL), while 17-hydroxyprogesterone (~20 nmol/L) and ACTH stimulation were within expected limits. The testosterone to dihydrotestosterone ratio was not increased. Imaging revealed no evidence of virilizing ovarian or testicular tumors. Genetic analysis identified a homozygous HSD17B3 mutation (NM_000197:c.277+4A>T), confirming the diagnosis of 17β-HSD3 deficiency.
Management and Outcome: After comprehensive psychological counseling, the patient expressed no gender dysphoria and elected to continue female gender identity. Pubertal induction with a GnRH analogue followed by transdermal estrogen therapy was initiated, with subsequent psychiatric follow-up. Surgical intervention (vaginoplasty) was planned in late adolescence.

Conclusion: This case highlights the importance of considering 17β-HSD3 deficiency in adolescents presenting with pubertal-onset virilization. A structured evaluation combining biochemical markers, imaging, and genetic testing is essential to guide diagnosis, while management requires a multidisciplinary, individualized, and patient-centered approach.

Keywords: 17β-HSD3 deficiency, Disorders of sex development, Pubertal virilization.

BILATERAL MULTIFOCAL RENAL TUMORS IN A YOUNG FEMELE: A RARE RENAL PRESENTATION OF BIRT-HOGG-DUBE SYNDROME

Poposka Elizabeta[1], Eftimovska-Otovikj Natasha[1], Popovska Bojana[1], Krstevska Teodora[1], Zlateska Kristina[1]
[1]*General City Hospital "8th September", 1000 Skopje; Department of Nephrology*

Background: Birt-Hogg-Dubé syndrome (BHDS) is a rare autosomal dominant disorder caused by mutations in the *FLCN* gene, associated with cutaneous fibrofolliculomas, pulmonary cysts, and increased risk of renal tumors.

Case Presentation: A 34-year-old woman with no prior medical history was admitted due to urosepsis, presenting with a 7-day history of high-grade fever, hypotension and bilateral flank pain. Physical examination revealed multiple dome-shaped, white papules on the scalp with alopecia, present for years, but never evaluated. Laboratory analysis showed elevated inflammatory markers (procalcitonin 3.58 ng/mL, C-reactive protein 219 mg/L and fibrinogen 6.5 g/L). Blood and urine cultures were positive for Escherichia colli. Imaging investigations showed multiple, well-circumscribed, mixed-echogenic lesions in both kidneys, supsected for renal abscesses. This was confirmed by contrast-enhanced computed tomography (CT). Under of targeted antibiotic therapy, inflammatory markers normalized; however, repeat ultrasound showed persistent renal lesions. Magnetic resonance imaging (MRI) demonstrated bilateral renal masses suspicious for renal cell carcinoma (RCC) or oncocytoma. The patient underwent staged bilateral nephron-sparing surgery. Histopathology confirmed clear cell RCC in the right kidney and two hybrid oncocytic/chromophobe tumors in the left kidney.
Given the multifoca and bilaterall renal tumors in a young patient, with characteristic skin findings, a hereditary syndrome was suspected. Genetic testing identified a pathogenic mutation in the *FLCN* gene, establishing the diagnosis of Birt-Hogg-Dubé (BHD) syndrome.

Conclusion: BHDS should be considered in young patients presenting with bilateral or multifocal renal tumors, particularly when associated with cutaneous lesions. Early diagnosis is essential for patient management, surveillance, and family screening.

Keywords: Birt-Hogg-Dubé syndrome, FLCN protein, Renal tumors, Bilateral renal cell carcinoma, Fibrofolliculomas, Nephron-sparing surgery.

THE PRICE OF DELAY: SYSTEMIC AA AMYLOIDOSIS IN A YOUNG MALE WITH MISSED FAMILIAL MEDITERRANEAN FEVER – A CASE REPORT

Poposka Elizabeta[1], Eftimovska-Otovikj Natasha[1], Popovska Bojana[1], Pavlovski Stefan[2], Dzekova – Vidimislinski Pavlina[3]

[1]General City Hospital "8th September", 1000 Skopje; Department of nephrology; 2 General City Hospital "8th September", 1000 Skopje, Department of gastroenterology, 3 University Clinic for nephrology, 1000 Skopje

Background: Familial Mediterranean Fever (FMF) is an autoinflammatory disorder characterized by recurrent episodes of fever and serosal inflammation, caused by mutations in the *MEFV* gene. If undiagnosed or untreated, FMF can progress to systemic AA amyloidosis, particularly affecting the kidneys and gastrointestinal tract.

Case Presentation: We report a case of a 31-year-old Albanian male with a a longstanding history of recurrent abdominal pain, fever, and arthralgia since childhood, previously misdiagnosed as functional gastrointestinal disorder. At the age of 31, he presented with nephrotic syndrome, generalized edema, and hypoalbuminemia. Kidney biopsy, and later gastrointestinal biopsy, confirmed AA amyloidosis. Genetic testing revealed a pathogenic heterozygous *MEFV* mutation (c.2080A>G, p.Met694Val) in cis with a variant of uncertain significance (c.442G>C, p.Glu148Gln). Based on clinical features and genetic findings, the diagnosis of FMF was established. Treatment with colchicine and interleuin 1 inhibitors led to significant clinical improvement and reduction in systemic inflammation, although nephrotic-range proteinuria persisted.

Conclusion: This case highlights the importance of early recognition of FMF, even in the presence of atypical or heterozygous genotypes. Delayed diagnosis may lead to severe complications such as systemic AA amyloidosis. Clinical suspicion should guide early testing and prompt treatment with colchicine and biologic treatment, which can improve outcomes and prevent irreversible organ damage.

Keywords: Familial Mediterranean Fever, MEFV protein, AA amyloidosis, Nephrotic syndrome, Autoinflammatory disease, Colchicine, Interleukin -1 Receptor Antagonist Protein.

SIMULTANEOUS PAPILLARY THYROID CARCINOMA AND INTRATHYROID PARATHYROID CARCINOMA AS AN INCIDENTAL FINDING IN A PATIENT WITH GRAVES' DISEASE

Nikolovski Filip[1], Pop Gjorceva Daniela[1], Kostadinovska Lenche[2]
[1]*Institute of Pathophysiology and Nuclear Medicine "Academic D-r Isak S. Tadzer",*
[2]*University Clinic of Oncology, Faculty of Medicine, University "Ss. Cyril and Methodius"- Skopje*

Background: Papillary thyroid carcinoma is the most common thyroid malignancy, while parathyroid carcinoma is among the rarest cancers accounting for only 0,005% of all malignancies. Simultaneous coexistence of papillary thyroid carcinoma and intrathyroid parathyroid carcinoma is an incredibly rare occurrence with only one other case documented in literature.

Case report: We present a case of a 53 year old female patient with Graves' disease diagnosed at our Institute upon the classic patient history and laboratory findings, with diffuse goitre and multiple colloidal afunctional nodules detected by thyroid ultrasound (US) and 99mTc scan. FNAB of the largest colloidal nodule (9x13 mm) was conclusive with benign thyroid nodule. The patient was treated with high doses of thyreostatics, achieving very brief remissions followed by relapses. Because of this she was referred for surgical treatment of the hyperthyreosis. In the preoperative evaluation hypercalcemia was noted-Ca=3.05(2,1-2,6mmol/L). There was no US suspicion for presence of parathyroid adenoma. A total thyroidectomy was performed and pathohistological finding revealed presence of papillary thyroid microcarcinoma (0.6 mm) in the right thyroid lobe along with an intrathyroid parathyroid carcinoma (20 mm) in the same lobe, with peripheral, subcapsular localization and intrathyroid infiltration. The patient was referred to an oncologist for further evaluation and treatment of the parathyroid carcinoma.

Conclusion: Clinicians should be aware that thyroid hypoechogenic nodules rarely can represent intrathyroid parathyroid tumours resulting with primary hyperparathyroidism, which suggests regular serum calcium level screening in patients with thyroid nodules.

Keywords: Thyroid carcinoma, Intrathyroid parathyroid carcinoma.

FAMILIAL RECURRENT HYDATIDIFORM MOLE, AN ULTRA-RARE CONDITION AFFECTING THE FORGOTTEN ORGAN

Frosina Trajkoska[1], Katerina Kubelka-Sabit[1,2], Dijana Plaseska Karanfilska[3], Todor Arsov[1]
[1] *Faculty of Medical Sciences, Goce Delcev University, Stip, Macedonia*
[2] *Clinical Hospital Acibadem Sistina, Skopje, Macedonia*
[3] *Macedonian Academy of Sciences and Arts (MASA)*

Introduction: Hydatidiform mole (HM) is an abnormal pregnancy affecting the trophoblast. Partial HM (PHM) is triploid, diandric monogynic, with maternally expressed p57 gene, whereas complete HM (CHM) is diploid, p57- androgenetic. CMPs carry higher risk for choriocarcinoma of 15%, compared with 1% risk in PHM. Familial recurrent hydatidiform mole (FRHM) is an ultra-rare autosomal recessive disorder, mostly due to biallelic pathogenic variants in NLRP7 gene. Affected women are predisposed to recurrent p57- biparental CHM. Successful pregnancies in FRHM are very rare – only 7% of couples and about 2% of all pregnancies result in livebirths.

Case report: We present a case of FRHM with a history of 5 molar/hydropic pregnancies over a period of four years. The diagnosis was suspected after the 5th molar pregnancy, which was p57- (villous cytotrophoblasts and stromal cells) biparental CHM. The first pregnancy was not investigated, pregnancy 2 (PHM, revised to hydroptic abortion) was p57+ and demonstrated an unusual digynic monoandric triploidy, pregnancy 3 (CHM, revised to hydroptic abortion) was p57+ (genetic testing not possible) and pregnancy 4 (CHM, revised to hydroptic abortion) was p57+ biparental diploid. Whole exome sequencing of the maternal blood sample revealed biallelic likely pathogenic NLRP7 variant. The couple was counselled about the reproductive outlook, risks and options.

Conclusion: Our case underscores the importance of early diagnosis, comprehensive genetic counseling to manage this rare, yet significant condition. Oocyte donation offers an option for having a healthy child, while avoiding the risk of recurrent molar pregnancies and the associated risk of malignancy.

Keywords: Familial recurrent hydatiform mole, p57 expression, Karyotype, NLRP7.

DIFFERENTIAL DIAGNOSTIC CHARACTERISTICS ACROSS NEUROMUSCULAR DISEASE IN THE MACEDONIAN PATIENT ADULT POPULATION

Ivan Barbov[1,2], Goce Kalcev[2]
[1]*University Clinic of Neurology, Skopje, North Macedonia*
[2] *National Alliance for Neuromuscular diseases and Neuroscience, GANGLION Skopje, 1000 Skopje, North Macedonia*

Introduction: The Individualized Neuromuscular Quality of Life (INQoL) questionnaire is a validated, disease-specific tool used to assess the impact of neuromuscular conditions on patients' quality of life and perceived disease burden.

Methods: A total of 30 adult patients with different neuromuscular conditions were included in the sample. We used an ANOVA test to determine significant differences between the means of various groups based on the diagnosis categories and their association to the measured variables.
Results: Regarding neuromuscular conditions, five individuals suffer from acute and two with chronic polyradiculoneuritis. Diabetic polyneuropathy, inflammatory polyneuropathy, myasthenic syndrome, rhabdomyolysis, facioscapulohumeral muscular dystrophy type 2, funicular myelosis, and amyotrophic lateral sclerosis each affect one participant. Three participants have spinal muscular atrophy, and familial amyloid polyneuropathy is seen in 11 participants. Myasthenia gravis was identified in two patients. The measured variables in the section of the symptoms were: scores of the muscle weakness, pain, fatigue, locking of the muscles, droopy eyelids, double vision, and swallowing difficulty separately. The measured variables of the section life domains were: score of activities, independence, social relationships, emotions, and body image. The measured variables in the section of the treatment effects were perceived treatment effects and expected treatment effects. The ANOVA test found significant differences between the means of various groups based on the diagnosis categories for the following measured variables: swallowing difficulty, perceived treatment effects and expected treatment effects.

Conclusion: "These preliminary findings indicate that the continued use of this assessment tool is a feasible approach for evaluating patients with neuromuscular diseases. Future research incorporating larger sample sizes and follow-up periods is warranted to further validate its applicability and clinical utility.

Keywords: Quality of life, ANOVA, Variables, Questionnaire, INQoL.

ACUTE KIDNEY INJURY IN AN INFANT WITH COWDEN SYNDROME

Ivan Akimovski[1], Haris Sulejmani[2], Elena Shukarova Angelovska[1], Nora Abazi Emini[1], Velibor Tasic[1]
[1]*University Children's Hospital Skopje, North Macedonia*
[2]*Medical Faculty Skopje, North Macedonia*

Introduction: Cowden syndrome, or PTEN hamartoma tumor syndrome (PHTS), is a rare autosomal dominant disorder caused by germline pathogenic variants in the PTEN tumor suppressor gene. The phenotype is highly variable, most often presenting with macrocephaly, developmental delay, autism spectrum features, mucocutaneous lesions, and increased lifetime cancer risk. Renal manifestations are mainly described in adults, with renal cell carcinoma being the most significant concern. In children, reports of kidney involvement remain scarce.

Case presentation: We report a 7-month-old male who presented with generalized edema and oliguria. Laboratory testing showed acute kidney injury with serum creatinine 168 μmol/L, blood urea 10.8 mmol/L, and uric acid 455 μmol/L. Renal ultrasound revealed bilaterally enlarged and hyperechogenic kidneys. Clinical examination identified macrocephaly, mild facial dysmorphism, hypotonia and moderate psychomotor delay. Conservative management led to complete recovery of renal function. Genetic analysis demonstrated a pathogenic variant in PTEN, confirming the diagnosis of PHTS.
Renal involvement in PHTS during childhood is poorly characterized. While adult patients are at high risk of renal cell carcinoma, pediatric cases typically describe benign cysts or dysplastic changes, and acute kidney injury is rarely reported. In our patient, AKI presented as reversible nephropathy with renal enlargement and hyperechogenicity. The mechanism remains uncertain but may relate to underlying developmental anomalies of the kidney associated with PTEN dysregulation in cellular growth and apoptosis pathways. This case highlights the need to consider PTEN mutations in infants with unexplained renal dysfunction, especially when syndromic features such as macrocephaly and developmental delay are present.

Conclusion: We describe a unique case of acute kidney injury in an infant with PHTS. This expands the spectrum of renal manifestations in childhood and underlines the importance of early recognition and genetic evaluation for guiding follow-up and counseling.

Keywords: Acute kidney injury, Cowden syndrome, Hamartoma.

ALPORT SYNDROME – CASE REPORT

Jovan Jovanoski , Aleksandar Necev[1], Neda Malenkov[2]

[1]*First Private General Hospital "Remedika"- Skopje*

[2]*Special Hospital for Orthopaedics and Traumatology "St. Erasmus "- Ohrid*

Introduction: Alport syndrome is a rare genetic disorder characterized by progressive kidney disease, hearing loss, and ocular abnormalities. It is caused by mutations in the genes encoding type IV collagen, crucial for the integrity of the basement membranes in the kidneys, inner ear, and eyes. This case report presents a patient with Alport syndrome, focusing on the clinical progression, diagnostic challenges, and treatment approach.

Methods: The patient, a 35-year-old male, presented with hematuria and proteinuria detected in early childhood. Family history revealed that several male relatives had kidney disease and hearing impairment. Initial investigations included urinalysis, renal function tests, and kidney biopsy, revealing glomerular basement membrane (GBM) thinning and splitting, consistent with Alport syndrome. Genetic testing confirmed a pathogenic variant in COL4A5 gene G624D indicating an X-linked inheritance pattern. Audiological and ophthalmological evaluations were conducted to assess the progression of hearing and vision deficits.

Results: Over time, the patient experienced worsening renal function, leading to chronic kidney disease (CKD). He also developed bilateral sensorineural hearing loss, requiring hearing aids, and anterior lenticonus in the eyes. The patient received angiotensin-converting enzyme (ACE) inhibitors to slow renal decline, and regular follow-up was maintained to monitor kidney function, hearing, and vision.

Conclusion: Alport syndrome requires early diagnosis and a multidisciplinary approach to management. Genetic testing is crucial for accurate diagnosis and family counseling. Treatment with ACE inhibitors has been effective in delaying renal disease progression. This case underscores the importance of regular monitoring of renal, auditory, and visual systems in patients with Alport syndrome to improve quality of life and delay the onset of end-stage renal disease.

Keywords: Alport syndrome, Genetic disorder, Glomerular basement membrane, X-linked inheritance.

BULIMIA NERVOSA COMPLICATED BY ACUTE PSYCHOSIS AND SLEEP DISORDER IN A 15-YEAR-OLD FEMALE: A CHALLENGING CASE REPORT

Kamelija Simeonova[1], Ajshe Isljam[1], Martin Angjelov[1], Risto Simeonov[3,4], Beti Gjurkova-Angelovska[2] Natasha Chuchkova-Nikchevska[2] Natali Jordanovska[5]
[1]PHI "Acibadem Sistina", Clinical Hospital, Skopje, Macedonia
[2]PHI "Acibadem Sistina", Clinical Hospital, Department of Pediatrics, Skopje, Macedonia
[3]PHI "Acibadem Sistina", Clinical Hospital, Department of Pediatric Surgery, Skopje, Macedonia
[4]Faculty of Medical Sciences, "Goce Delchev" University in Shtip, Macedonia
[5]PHI "Atelas- Centar za bolka" - Skopje, Macedonia

Introduction: Eating disorders such as anorexia and bulimia nervosa are increasingly prevalent among adolescents worldwide. Most patients are initially evaluated by general practitioners, and diagnosis may be delayed as symptoms overlap with other medical or psychiatric conditions. Recognizing rare but serious comorbidities is essential, as misdiagnosis can lead to significant morbidity.

Case Presentation: We present the case of a 15-year-old female admitted to the Urgent Pediatric Centre at PHI "Acibadem Sistina" Clinical Hospital with recurrent vomiting, dehydration, loss of appetite, hypoglycemia, and significant weight loss. On admission, laboratory investigations were performed, and the patient was hospitalized for further evaluation. A head CT scan revealed no intracranial abnormalities. Due to severe psychiatric and neurological symptoms, including acute psychosis and sleep deprivation, urgent consultation with a child and adolescent psychiatrist was requested. Pharmacotherapy was initiated, leading to gradual improvement in clinical and psychiatric symptoms. The patient was discharged in stable condition with recommendations for regular outpatient follow-up.

Conclusion: This case emphasizes the diagnostic challenges posed by overlapping features of eating disorders and psychiatric conditions in adolescents. Neurological and behavioral symptoms may mimic or mask underlying eating disorders, delaying appropriate treatment. A multidisciplinary approach involving pediatricians, psychiatrists, and other specialists is crucial to ensure accurate diagnosis, timely intervention, and improved outcomes in this vulnerable population.

Keywords: bulimia nervosa, acute psychosis, sleep deprivation, vomiting, psychopathology, child and adolescent psychiatry

EDWARDS SYNDROME - OUR EXPERIENCE AT NEONATAL INTENSIVE CARE UNIT

Hristina Mandzukovska, Aspasija Sofijanova, Silvana Naunova Timovska, Besim Vejseli, Sukarova Elena
University Clinic for Pediatric Diseases, 1000 Skopje, Republic of North Macedonia, Faculty of Medicine, Ss. Cyril and Methodius, University in Skopje, 1000 Skopje, Republic of North Macedonia

Background: Edwards Syndrome – Trisomy 18 syndrome was first reported by Edwards in 1960. It is a rare chromosomal disorder due to presence of extra copy of chromosome 18. The prevalence is ranges from 1 in 3600 to 1 in 10,000 newborns and 90% of newborns do not survive beyond the first week of life. Edward syndrome can be identified in perinatal period by ultrasonography up to 97% cases.
The Edwards Syndrome usually is associated with multiple congenital malformations affected cardiovascular, gastrointestinal, craniofacies renal and skeletal abnormalities. There are three types of Edwards Syndrome, complete type - 90%, partial type -less 5% and mosaic trisomy 18 type over 2%.
The major percent of newborn infants do not survive beyond the first month of life; very small percent about 8 % of infants live longer than one year. Almost all of these infants are hospitalized in NICU for need of mechanical venitaltion and intensive medical care.

Case report: Our clinical experience with Edwards Syndrome newborns is very inssuficiensy. In the last three years in NICU, we have only two cases of newborns with Edwards Syndrome, both of them, unfortunately died in the first month of life.
The first newborn at age of 3 days was transferred from neonatology department after worsing of general condition (apnea, bradycardia - 40 bpm and perioral cyanosis). In NICU immediately intubated, put on conventional ventilation and sedated. The newborn was with dysmorphic features (small face, micrognathia, low set ears, epicanthus, hypertelorism, short neck, hypertrichosis on legs). Due to phenotypic characteristics typical of Edwards syndrome cytogenetic analyses were done and confirmed the diagnosis of Trisomia 18 (karyotype 47 XY+18). Echography of the heart confirmed following heart defects: hypoplastic aortic arch with a bicuspid aortic valve. Ultrasound of others organ systems were normal. During NICU stay the general condition in the next 10 days of the newborn with progressive worsening (respiratory acidosis, apnea, hypotension, bradycardia and general cyanosis), he died at age of 13 days.
The second newborn at age of 4 hours with prenatal diagnosis of Trisomia 18 was transferred from the hospital in Struga. Intubated at the admission put on invasive conventional ventilation and sedated. Clinically, the newborn showed phenotypic characteristics of Edwards syndrome (open fontanelle, small face, ptosis, micrognatia,hypoplasic mandibular, hypoplastic neck and chest). Ultrasound of the heart confirmed ventricular septal defect, atrial septal defect and pulmonary artery stenosis. Ultrasound of brain, kidney and abdomen were normal. Although an early application of intensive therapy started from the first hospital day, the general condition of the newborn progressively worsed; hemodynamically unstable with hypotension and bradycardia, apnea and respiratory insufficiency. At the age of 11 days the newborn died.

Conclusion: Edwards syndrome is a rare genetic disorder associated with multiple congenital malformations. Edward syndrome is diagnosed prenatally by several procedures, basis of maternal health; it is very important to confirm the syndrome and help in identifying unexpected anomalies.

Keywords: Edwards Syndrome, infants, Abnormalities, NICU.

AUTOIMMUNE POLYENDOCRINOPATHY CANDIDIASIS ECTODERMAL DYSTROPHY (APECED) SYNDROME: A CLINICAL PERSPECTIVE

Marko Simunovic
University Hospital of Split, Department of pediatrics, Division of pediatric endocrinology
University of Split School of Medicine

Introduction: Autoimmune polyendocrinopathy candidiasis ectodermal dystrophy (APECED) is a rare monogenetic autosomal recessive disorder caused by a mutation in the autoimmune regulator (AIRE) gene characterized by complex phenotypic characteristics discovered over years of follow-up. Today, more than 120 mutations of the AIRE gene are reported and prevalence varies depending on the population (Finland 1:14,000, Slovenian 1:43,000, Norway 1:80,000 and Ireland 1:130,000). A clinical diagnosis of APECED is defined by the presence of two out of the three components of the classical triad: hypoparathyroidism, Addison's disease (AD), and chronic mucocutaneous candidiasis (CMC).

Results: We present our patient population of 8 patients which were recruited in the last 40 years in Southern Croatia. All of our patients had the same homozygous mutation R257X (c.769C > T) in the AIRE gene. The overall prevalence of APECED syndrome is estimated to be 1 in 75,000. The most common initial manifestation of the disease was onychodystrophy, while the first major component of APECED syndrome was chronic mucocutaneous candidiasis.

Conclusion: APECED is a "multi-faced" disease based on the very unpredictable and inconsistent onset of major components. Our findings further emphasize the heterogeneity of the phenotypes of APECED syndrome as a truly multifaced disease, and possibly indicate the importance of onychodystrophy as new warning signs for the APECED syndrome.

Keywords: APECED syndrome, AIRE gene mutation, Chronic mucocutaneous candidiasis.

A CHALLENGING CASE OF A 3-YEAR-OLD CHIILD WITH BILATERAL CYSTINE LITHIASIS -MINIMAL INVASIVE SURGICAL APPROACH

Martin Angjelov[1], Risto Simeonov[2,3]**,** Kamelija Simeonova[1], Sotir Stavridis[4], Vladimir Lozanovski[4], Natali Jordanovska[5]
[1]PHI "Acibadem Sistina" Clinical Hospital, Skopje, Macedonia
[2]PHI "Acibadem Sistina" Clinical Hospital, Department of Pediatric Surgery, Skopje, Macedonia
[3]Faculty of Medical Sciences, "Goce Delchev"University in Shtip, Macedonia
[4]PHI "Acibadem Sistina" Clinical Hospital, Department of Urology, Skopje,Macedonia
[5]PHI "Atelas- Centar za bolka" – Skopje, Macedonia

Introduction: Cystinuria is a rare genetic disorder characterized by impaired renal tubular reabsorption of cystine and other dibasic amino acids, leading to elevated urinary cystine concentrations and recurrent stone formation. Cystine stones are typically resistant to standard therapies and may cause flank pain, hematuria, urinary tract infections (UTIs), and obstructive uropathy.

Case Presentation: We report a 3-year-old girl referred by a pediatric nephrologist for recurrent febrile UTIs, elevated inflammatory markers, and diffuse abdominal pain. Family history was positive for urolithiasis. Laboratory testing and urine culture were performed, and due to clinical suspicion, CT native stone protocol imaging was obtained. It revealed bilateral renal calculi and multiple ureteral stones. The patient was urgently admitted to the Department of Pediatric Surgery at Clinical Hospital "Acibadem Sistina", for operative management. Under general anesthesia, flexible ureterorenoscopy (FURS) with laser lithotripsy was performed. Using the "popcorn" technique, a stone-free status was achieved bilaterally. Double J stents were placed according to protocol. Postoperative radiographic evaluation confirmed complete clearance of urinary stones.

Conclusion: Management of cystinuria aims to reduce recurrent stone formation through adequate hydration, dietary modification, and pharmacological prophylaxis. In pediatric patients, modern minimally invasive techniques such as FURS with laser lithotripsy represent an effective and safe alternative to open or percutaneous surgery, offering significant benefits for both patient recovery and surgical outcomes.

Keywords: Cystinuria, Female child, Surgical approach, Laser-lithotripsy, Management.

UNILATERAL RENAL AGENESIS ASSOCIATED WITH CONTRALATERAL URETEROCELE AND ECTOPIC URETER INSERTION: A RARE CASE REPORT

Milkica Pashoska Vasileska[1], Ivan Akimoski[2], Natalija Chaneva[1], Slavica Todorovska[3], Nora Abazi Emini[2], Velibor Tasic[2,3]
[1]*Depatrment od Paediatric Radiology, University Institute of Radiology – Skopje, North Macedonia*
[2]*University Children's Hospital Skopje, North Macedonia*
[3]*PZU Pantelejmon, Skopje, North Macedonia*

Introduction: Congenital anomalies of the kidney and urinary tract (CAKUT) represent 20–30% of all prenatally detected malformations. Unilateral renal agenesis occurs in approximately 1 in 1,000–2,000 live births, while ureterocele is reported in 1 in 500–4,000 children, most often in association with duplex systems. The combination of renal agenesis with a contralateral ureterocele is exceptionally rare and only sporadically described in the literature.

Case presentation: We present a boy multicystic displastic ecopic right kidney and ureterocel on the right side. He was followed regularly by ultrasound, which showed normal growth and preserved function of the left kidney. Until the age of nine, no abnormalities were detected. At that time, ultrasound revealed the presence of a ureterocele on the right side.
Magnetic resonance urography demonstrated that the right ureter coursed aberrantly from the aortic bifurcation toward the right side of the pelvis and drained ectopically into the urinary bladder, forming a ureterocele. The right ureter in its proximal part had a 2-3 cystic changes which indicate that the kidney missing might have been a multicystic displastic ectopic one.
This case illustrates an unusual anatomical-functional constellation: renal displasia on one side, with the ipsilateral ureter showing aberrant trajectory and ending in a ureterocele. Early ultrasound follow-up did not reveal abnormalities, emphasizing the importance of long-term surveillance in children with a solitary kidney. Although the prevalence of ureterocele in the general pediatric population is low, its occurrence in association with solitary kidney poses significant clinical risk. Obstructive uropathy and urinary tract infections may compromise the function of the single kidney, with long-term consequences.

Conclusion: The presented case highlights a rare association of unilateral renal agenesis and contralateral ureterocele with ectopic ureteral insertion. Children with a solitary kidney require not only monitoring of growth and function but also periodic detailed morphological assessment, as secondary anomalies may manifest later in childhood. Early detection of such abnormalities is crucial to preserving renal function and improving long-term outcomes.

Keywords: CAKUT, Kidney agenesis, Ureterocella.

THE SILENT DAMAGE: LATE DIAGNOSIS OF HINMAN SYNDROME IN ADOLESCENCE

Natalija Cokleska[1], Julija Gjorgievska[2], Shqiponja Kasa[2], Besa Alili-Bajrami[2], Nora Abazi-Emini[2]
[1]University Clinic for Pediatric Surgery - Faculty of Medicine, Skopje, University Ss. Cyril and Methodius, Skopje, North Macedonia
[2]University Children's Hospital - Faculty of Medicine, Skopje, University Ss. Cyril and Methodius, Skopje, North Macedonia

Background: Hinman Syndrome, also known as non-neurogenic neurogenic bladder is a rare and complex urological condition that mimics neurogenic bladder dysfunction without any identifiable neurological cause. The pathophysiology is believed to involve learned maladaptive voiding behaviors, often rooted in early childhood. The condition mimics neurogenic bladder dysfunction, leading to urinary retention, incontinence, recurrent urinary tract infections, and progressive renal damage. Management requires a multidisciplinary approach, including behavioral therapy, pharmacologic intervention, and in severe cases, surgical correction.

Case presentation: A 12-year-old girl was referred for evaluation following signs of a lower urinary tract infection and abnormal renal function parameters. On presentation, she was clinically stable, afebrile, and had normal vital signs. Initial imaging, including renal ultrasound and CT urography, showed severe bilateral hydroureteronephrosis with poor corticomedullary differentiation. The bladder was notably enlarged, with irregular contours and a trabeculated wall. Laboratory workup revealed moderate chronic kidney disease (eGFR 46 ml/min/1.73m²), pyuria, and non-nephrotic range proteinuria. Despite these findings, the patient reported no urinary symptoms—no dysuria, enuresis, or signs of bladder dysfunction. Bowel habits were regular, and MRI of the lumbar spine was normal, excluding neurogenic causes. Voiding cystourethrography revealed severe bilateral vesicoureteral reflux, a trabeculated bladder, and multiple diverticula, consistent with advanced bladder dysfunction. Management was initiated with clean intermittent catheterization and prophylactic antibiotics. Renal function showed improvement on follow-up (eGFR increased to 58 ml/min/1.73m²), and repeat renal ultrasound demonstrated reduced urinary tract dilation. A urodynamic study is planned to further assess bladder compliance and detrusor function, which will guide long-term management.

Conclusion: Hinman Syndrome can silently cause serious kidney damage if not diagnosed early. This case shows the importance of timely recognition and multidisciplinary care to prevent long-term complications.

Keywords: Hinman syndrome, Renal impairment, Bladder dysfunction.

A CASE REPORT OF RELAPSING THROMBOTIC THROMBOCYTOPENIC PURPURA IN A YOUNG FEMALE PATIENT

Olivera Gjeorgjieva Janev[1], Martin Stojanoski[1], Marija Popova Labachevska[1], Zlate Stojanoski[1], Sonja Genadieva Stavrikj[1]
[1]University Clinic of Hematology, Skopje

Background: Thrombotic thrombocytopenic purpura (TTP) is a rare, life-threatening haematological disorder caused by a severe deficiency of the ADAMTS13 enzyme, leading to microvascular platelet aggregation and organ damage. It exists in congenital and acquired (immune-mediated) forms. The acquired form is often linked to autoimmune conditions or infections and is characterized by inhibitory autoantibodies against ADAMTS13.

Case Presentation: A young female patient was first admitted at our clinic in October 2019 because of Coombs positive haemolytic anaemia and thrombocytopenia. Fast response to parenteral corticosteroids was achieved, with subsequent transition to oral steroids, which were finally discontinued in December 2019. Meanwhile she was tested for systemic rheumatologic diseases that showed to be negative. In June 2020, she developed recurrent thrombocytopenia with petechiae, requiring hospitalization and corticosteroid therapy. A further relapse in November 2020 was treated with Rituximab (6 doses), followed by corticosteroid maintenance and Resochin.
In June 2023, she was rehospitalized for the fourth occurrence of autoimmune haemolytic anaemia and thrombocytopenia, only that time Coombs test was negative. Bone marrow biopsy was performed showing hypocellular bone marrow, and ADAMTS13 assay revealed severely reduced ADAMTS13 activity with high levels of inhibitory antibodies. The patient was successfully treated with thirteen sessions of plasma exchange and corticosteroids.
Unfortunately in 2025, she presented at the clinic with triad of symptoms: anaemia, profound thrombocytopenia, petechiae, and neurological symptoms. Laboratory testing was consistent with relapsing immune-mediated TTP with markedly low ADAMTS13 activity. She underwent 10 plasma exchanges and was initiated on second-line therapy with Rituximab. After three doses, she achieved full clinical and haematological remission.

Conclusion: This is a case of immune-mediated TTP with multiple relapses, initially responsive to corticosteroids but requiring escalation to Rituximab. Close laboratory monitoring for prompt recognition of relapse and repeated plasma exchange were essential for achieving remission and preventing life-threatening complications.

Keywords: Thrombotic thrombocytopenic purpura, Plasmapheresis, Monoclonal antibodies.

PRESENTATION OF SOME RARE DISEASE ASSOCIATED WITH CONGENITAL HEART DISEASE - CASE BY CASE

Rinor Bejiqi, A. Maloku, A. Mustafa, A. Keka, Blend Bejiqi
[1]*Department of Pediatrics Cardiology, Pediatric Clinic, UCC of Kosovo, Republic of Kosovo*

Introduction: Rare diseases are conditions that are reported as less than 1 in 2000 live births; 80% of them are based on genetic disturbances. They can affect all parts of the human body and in a significant number are associated with congenital heart diseases (CHD). In most cases, cardiovascular symptoms dominate the clinical manifestations of rare diseases and are the main cause of morbidity and mortality, especially in childhood.

Aim of presentation: The purpose of this presentation is to present some cases of rare diseases associated with CHD, where leading clinical symptoms are from CHD.

Methodology: Retrospectively we analyzed recorded data of some children diagnosed with rare diseases, associated with congenital disease.

Presented cases: In this presentation we presented a few children with rare diseases, accompanied by CHD. In the first child, there was primary hypertrophic cardiomyopathy which was the cause of loss of consciousness and severe heart rhythm disorders. The second child has restrictive cardiomyopathy, diagnosed in neonatal age. The third child has developed primary pulmonary hypertension, while the fourth presented child belongs to the group of mesenchymopathies with Loeys-Dietz syndrome, accompanied by giant dilation of the ascending aorta.

Conclusion: All the presented children belong to the group of children with rare diseases and in the clinical presentation are dominated by the symptomatology of associated CHD.

Key words: Rare disease, Congenital heart disease, Primary hypertrophic cardiomyopathy, Loeys – Dietz syndrome.

SEVERE NEONATAL PRESENTATION OF Xp21 CONTIGUOUS GENE DELETION: ADRENAL CRISIS AND NEUROMUSCULAR INVOLVMENT

Sandra Stankovic
Pediatric Clinic, University Clinical Center Nis
Medical Faculty Nis

Background: Xp21 contiguous gene deletion syndrome is a rare X-linked disorder involving deletions of DMD, GK, and NR0B1 (DAX1), leading to a combination of Duchenne muscular dystrophy, glycerol kinase deficiency, and congenital adrenal hypoplasia. Diagnosis can be delayed due to overlapping symptoms, especially in critically ill infants.

Case Reports: We describe two male infants presenting in early life with adrenal insufficiency, electrolyte imbalance, hyperpigmentation, and hypotonia. Biochemical findings included elevated ACTH, low cortisol, high CK, and pseudo-hypertriglyceridemia. In the first case, delayed diagnosis led to sudden death at 7 months. In the second case, early clinical suspicion enabled timely genetic testing and family screening. MLPA revealed DMD gene deletion in both cases. In the second case, molecular karyotyping confirmed deletion at Xp21.3–p21.1; the mother and sister were also carriers.

Conclusion: Clinicians should consider Xp21 syndromes in male infants with adrenal insufficiency and neuromuscular or metabolic signs. Early recognition and genetic testing are crucial for accurate diagnosis, effective management, and informed family counseling.

Keywords: Xp21 contiguous gene deletion syndrome, Adrenal insufficiency, Duchenne muscular dystrophy

CASE REPORT OF A PATIENT WITH ATYPICAL PROGEROID SYNDROME ON THERAPY WITH METRELEPTIN

Todorovic Sladjana[1], Milenkovic Tatjana[1], Mitrovic Katarina[1,2], Vukovic Rade[1,2], Panic Zaric Sanja[1], Cvetkovic Dimitrije[1]
[1]Institute for Mother and Child Health Care of Serbia "Dr. Vukan Cupic", Belgrade, Serbia
[2]Faculty of Medicine, University of Belgrade, Serbia

Background: Atypical progeroid syndrome, which belongs to the group of congenital lipodystrophies, is a very rare disease. Clinical manifestations can be very diverse. The metabolic consequences of lipodystrophy syndromes are insulin resistant diabetes, hypertriglyceridemia and hepatic steatosis, and they are difficult to treat, resulting in significant risks of complications and of decreased quality of life.
Case report: We present a girl who has been monitored since the age of six months, when „cafe au late“spots was noticed, she was diagnosed with neurofibromatosis type 1. Because of limited range of motions of the knees and ankles, at the age of seven years she was diagnosed with scleromyositis. She was initially treated with methotrexate, prednisolone, folic acid and alphaD3. At the age of 11 years, she was examined by nephrologists because of dysuric problems and abdominal pain. She had mandibular hypoplasia, hypertelorism, prominent eyes, beaked nose. Skin showed mottled hyper- and hypopigmentations on the extremities, telangiectasias on the legs. There was generalized loss of subcutaneous fat, with prominent muscle. Acanthosis nigricans at the neck, hyperkeratosis on the knees and elbows were noticed. Cardiac examination revealed a grade 3/6 mesosystolic murmor. The liver was palpable 8 cm below the right costal margin. At that time, for the first time there was assumption that the girl had some kind of congenital lipodystrophy. Because of the high morning blood glucose levels, oral glucose tolerance test was performed. OGT test revealed diabetes (glucose 13.2 mmol/l at the 120 min; normal level is below 7.8 mmol/l), with very high insulin concentration (1408 mU/l). Lipids were measured too: cholesterol 4.75 mmol/l, triglycerides 10.54 mmol/l (very high concentration), HDL-cholesterol 0.61 mmol/l (low concentration). Level of serum leptin was very low: 1.3 ng/ml (reference range 2.43-28.0). Genetic testing revealed mutation in LMNA gene (c.139hetG>T; p.D47Y) on chromosome 1. According to phenotype, metabolic abnormalities and genetic investigation, diagnosis of atypical progeroid syndrome was established (University of Texas Southwestern Medical Center, Dallas, USA). We started treatment with low-fat diet with MTC oil, ciprofibrate and metformin. After a long battle to import the metreleptin to Serbia, girl received this drug in October 2013. at the age of 14 years. At that point, hyperglycemias were recorded, with a high level of HbA1c (9,4 %), hyperlipidemia (cholesterol 5,37 mmol/l, triglycerides 19,43 mmol/l, HDL- cholesterol 0,50 mmol/l), very high insulin level (168,60 mIJ/l) and proteinuria (942,0 mg/24h). After introducing metreleptin into the therapy, metabolic effects were amazing with a almost normal results after 6 months of therapy. She is followed up in the outpatient clinic and her last visit was on October 2017, when she was referred to adult endocrinologist. She is still getting metreleptin.
Conclusion: Atypical progeroid syndrome is an example where mutations in one gene can give very diverse clinical manifestations, described as different diseases. This is an extremely rare form of diabetes mellitus. Metreleptin is the only specific therapy for lipodystrophy syndromes, it is very efficient, and we hope that this therapy will lower the risk for complications in adult life in our patient.

Keywords: Atypical progeroid syndrome, Congenital lypodystrophy, LMNA gene mutation.

WEGENER'S GRANULOMATOSIS IN A YOUNG PATIENT - A DIAGNOSTIC CHALLENGE

Slavica Kitanoska[1], Nebojsa Risteski[1]
[1]Polyclinic Prima Medica, Kicevo

Introduction: Wegener's granulomatosis, also known as granulomatosis with polyangiitis (GPA), is a rare, potentially life-threatening autoimmune vasculitis characterized by granulomatous inflammation and necrosis of small- to medium-sized blood vessels. The aim is to highlight the importance of early recognition and serological testing in patients with atypical, chronic headaches and respiratory symptoms that do not respond to standard therapy.

Case Presentation: A 24-year-old male with unremarkable personal and family history first presented in March 2024 with severe unilateral headaches and facial pain on the left side, occasionally accompanied by epistaxis from the same side. Laboratory findings were normal, while X-ray suggested acute sinusitis. Antibiotic and symptomatic therapy was initiated, but without improvement. A head CT scan also indicated sinusitis, and the patient received parenteral antibiotics, again with no clinical response. Consultations with a neurologist and ENT specialist resulted in further symptomatic treatment, which remained ineffective. The patient's treatment in Macedonia lasted five months. He returned in September 2025 with medical records from Italy, where immunoserological testing (c-ANCA: anti-neutrophil cytoplasmic antibodies) confirmed the diagnosis of Wegener's granulomatosis. Immunosuppressive therapy (cytostatics + corticosteroids) and anticoagulant therapy were initiated. The patient's general condition improved, with resolution of headaches, but laboratory tests revealed visceral organ involvement, including elevated BNP and creatinine levels.

Conclusion: This case underscores the importance of a multidisciplinary approach and maintaining clinical suspicion when faced with atypical courses of common symptoms. Wegener's granulomatosis should be considered in young patients with persistent, atypical headaches and sinusitis unresponsive to standard therapy. Early recognition and serological confirmation (ANCA testing) are crucial for timely initiation of immunosuppressive treatment and prevention of progressive organ damage.

Keywords: Wegener's granulomatosis, Headache, Sinusitis, Therapy.

PCARE-ASSOCIATED CONE-ROD DYSTROPHY: CASE REPORT

Stefan Pandilov[1], Natasha Shekerinov[1], Jana Nivichka Kjaeva[1], Emilija Shukarova Stefanovska[2], Dijana Plaseska-Karanfilska[2]

[1]*University Clinic for Eye Diseases, Faculty of Medicine, Ss. Cyril and Methodius University in Skopje, Skopje, North Macedonia, The Republic of*

[2]*Macedonian Academy of Sciences and Arts, Research Centre for Genetic Engineering and Biotechnology, Skopje, North Macedonia, The Republic of*

Background: PCARE encodes the photoreceptor cilium actin regulator (PCARE), a ~1,289–amino-acid protein expressed in the connecting cilium that orchestrates actin-mediated outer segment disk formation and renewal on photoreceptor cells. We report a rare, genetically confirmed case of PCARE-associated cone-rod dystrophy, first in our country, emphasizing the importance of early recognition and the potential therapeutic window provided by foveal sparing.

Case presentation: A 43-year-old male presented with a more than 10-year history of progressive visual decline and impaired dark adaptation. Best-corrected visual acuity was −0.1 logMAR in the right eye and −0.5 logMAR in the left. Fundus examination revealed macular geographic atrophy with foveal sparing, diffuse granular retinal changes and peripheral pigment spicules. Short-wavelength autofluorescence imaging demonstrated hypoautofluorescence consistent with geographic atrophy in the macula, a peripapillary hypoautofluorescence ring, and granular hyper-/hypoautofluorescence along the vascular arcades. Optical coherence tomography showed thinning of the outher retinal layers and retinal pigment epithelium atrophy with preserved fovea. Automated perimetry (24-2) indicated widespread scotomas. Full-field electroretinogram (ERG) responses were nearly extinguished across rod- and cone-mediated ERGs. Molecular genetic testing via whole-exome sequencing identified compound heterozygosity for pathogenic nonsense variants (c.1949G>A (p.Tp650Ter) inherited from his father and c.3002G>A (p.Trp1001Ter) inherited from his mother) in exon 1 of the PCARE gene, confirming autosomal recessive PCARE-associated retinopathy. The patient was counseled that PCARE-associated retinopathy is a rare inherited retinal dystrophy with no curative therapy at present. However, he was informed about potential future gene-based therapy to maintain his remaining visual function.

Conclusion: PCARE-associated retinopathy is a severe photoreceptor ciliopathy characterized by cone-rod dysfunction and macular atrophy. Notably, foveal sparing can preserve central vision into midlife, presenting a critical window for emerging gene therapy strategies. Early genetic diagnosis is essential for patient counseling, prognosis, and inclusion in future interventional trials.

Keywords: PCARE gene, Photoreceptor ciliopathy, Cone-rod dystrophy.

CRACKING THE NUTCRACKER: RAPID DIAGNOSIS OF A VASCULAR ENIGMA

Svetlana Lazarevska-Gogoska[1], Luljeta Jusufi-Osmani[1], Sandra Aleksova[1], Biljana Ognenoska[2], Nora Abazi-Emini[1]

[1] University Children's Hospital - Faculty of Medicine, Skopje, University Ss. Cyril and Methodius, Skopje, North Macedonia

[2] University Institute for Radiology - Faculty of Medicine, Skopje, University Ss. Cyril and Methodius, Skopje, North Macedonia

Background: Nutcracker syndrome is rare vascular disorder where the left renal vein is compressed between the aorta and superior mesenteric artery. In children often presents with isolated, painless hematuria and may go unnoticed without targeted imaging. Affected children are typically thin and asthenic. While many remain asymptomatic, symptomatic cases may show gross hematuria, flank pain, or varicocele. Diagnosis relies on imaging, especially Doppler ultrasound or CT angiography, to confirm compression of the left renal vein. Nutcracker syndrome is classified into anterior, posterior, or combined types based on the anatomical site of compression.

Case presentation: We present the case of a 7-year-old asthenic girl with intermittent, painless gross hematuria persisting over one month. A comprehensive biochemical workup yielded normal results. The patient exhibited no dysuria, renal colic, or family history of kidney disease, and screening for hematuria in relatives was negative. The urinary tract ultrasound was unremarkable, and urine cultures were sterile. Microscopic analysis revealed eumorphic erythrocytes, and SDS-PAGE electrophoresis excluded a glomerular origin of hematuria. Given the clinical suspicion of Nutcracker Syndrome, CT angiography was performed, revealing compression of the left renal vein between the aorta and superior mesenteric artery, with an aortomesenteric angle of approximately 11 degrees - confirming the diagnosis.

Conclusion: This case highlights the importance of considering Nutcracker Syndrome in thin, asthenic children who present with isolated, painless gross hematuria and unremarkable routine work-up. When ultrasound fails to reveal a source, targeted vascular imaging, ideally CT angiography, can confirm left renal vein compression by demonstrating a narrowed aortomesenteric angle.

Key words: Nutcracker syndrome, Gross hematuria, CT angiography.

DO WE ALWAYS DETECT AS WE EXPECT - A RARE PATHOGENIC VARIANT IN THE GRIN2B GENE IN A 10-YEAR-OLD MARFANOID GIRL WITH HASHIMOTO'S THYROIDITIS AND HYPOTHYROIDISM

Tamara Stamenkovska Gjorgievska[1], Ivana Stojanoska[2], Ana Pajakovska[1], Svetlana Lazarevska-Gogoska[3], Aleksandra Janchevska[1]

[1]*University Children's Hospital, Medical Faculty, Skopje, RN Macedonia*

[2]*General Hospital of Ohrid, RN Macedonia*

[3] *IPH Institute for Lung Diseases in Children, Kozle, RN Macedonia*

Introduction: Marfanoid habitus, characterized by disproportionately long limbs, arachnodactyly, and other skeletal features, is typically associated with Marfan Syndrome (MFS) or related connective tissue disorders, often linked to the FBN1 gene. Hashimoto's thyroiditis (HT) is the most common cause of acquired hypothyroidism in children. The GRIN2B gene on chromosome 12 encodes the GluN2B subunit of the NMDA receptor, which plays a key role in synaptic plasticity and cognitive development. Pathogenic variants are linked to neurodevelopmental disorders such as epilepsy, intellectual disability, and autism spectrum disorder.

Case report: We present a 10-year-old girl with significant marfanoid features, including tall stature (0.67 SDS) for her weight (-1.28 SDS), mild scoliosis, and joint hypermobility. She had a palpable thyroid gland with irregular contours, more pronounced in the right lobe.

The patient had seizures in early childhood, which required antiepileptic therapy by the age of three. She subsequently developed learning difficulties and experienced recurrent seizures. Several cousins on both parental sides had febrile and afebrile seizures.

A thyroid functional test revealed overt hypothyroidism secondary to Hashimoto's thyroiditis (elevated TSH, low FT4, positive anti-TPO antibodies), which indicated commencement of Levothyroxine replacement therapy. Cardiac ultrasound detected mitral valve prolapse.

Comprehensive molecular analyses for connective tissue disorders and other syndromes were negative, but on the contrary, revealed a rare, de novo pathogenic variant in the GRIN2B gene, c.4003C>A (p. Pro1335Thr) in exon 14, explaining the patient's neurological features and neurodevelopmental abnormalities.

Conclusions: Herein, we underscore the importance of detailed phenotypic characterization and broad genetic evaluation in pediatric patients with overlapping clinical features. Careful family history, multidisciplinary work, and molecular diagnostics are essential in children with complex presentations.

Keywords: Marfanoid habitus, Neurodevelopmental disorder, Hypothyroidism, Seizures, GRIN2B gene.

X-LINKED HYPOPHOSPHATEMIA - NEW TREATMENT OPTIONS

Tamara Žigman
Department of pediatrics, Division for medical genetics and inherited metabolic disorders, University Hospital Center Zagreb, Zagreb, Croatia
University of Zagreb, School of Medicine, Zagreb, Croatia

Bacground: X-linked hypophosphatemia (XLH) is a rare genetic disorder characterized by impaired tubular phosphate reabsorption, leading to chronic hypophosphatemia and rickets. It is caused by mutations in the PHEX gene, resulting in elevated levels of fibroblast growth factor 23 (FGF23). It is secreted by osteocytes and osteoblasts and its functions include: decreased phosphate reabsorption in the renal tubules (leading to increased phosphate excretion in urine) and suppressed 1α-hydroxylase activity, reducing the synthesis of active vitamin D, which in turn additionally decreases intestinal phosphate absorption.
Traditional treatment options have been based on improving bone mineralization and relied on oral phosphate supplements and active vitamin D analogs (e.g., calcitriol). These treatments often had limited efficacy and were associated with complications such as nephrocalcinosis and secondary hyperparathyroidism.

Case presentation: I present a female patient, now at the age of 3,5 years, with an antenatal diagnosis of XLH (due to positive family history), with modest success of supplementary treatment which she started from birth and with ongoing disease progression. She started treatment with burosumab from very early age (from 2 years of age on) and had remarkable treatment outcomes. She is the first patient treated with burosumab in Croatia.

Conclusion: A significant advancement in XLH treatment is the development of burosumab, a monoclonal antibody that targets and inhibits FGF23. Clinical trials have demonstrated that burosumab significantly improves serum phosphate levels, bone mineral density, growth in children, and quality of life in both pediatric and adult patients. It is now approved for use in many countries and represents a shift toward targeted, disease-modifying treatment.

Keywords: X-linked hypophosphatemia, Fibroblast growth factor 23, Burosumab.

ALAZAMI SYNDROME: FIRST REPORTED CASE IN THE ALBANIAN POPULATION

Vjosa M. Kotori, Afrim Kotori, Elida Krasniqi, Ilir Ahmetxhekaj

Background: Alazami Syndrome (AZ) is a rare autosomal recessive disorder caused by mutations in the LARP7 gene. It is characterized by global developmental delay, intellectual disability, distinctive craniofacial features, and postnatal growth retardation. To date, reported cases are limited, and this study presents the first documented case in the Albanian population.

Case Presentation: We report a case of a 3-year-old Albanian boy, born to non-consanguineous parents, presenting with multiple dysmorphic features and severe growth delay. Clinical findings included a triangular face, prominent forehead, deep-set eyes, distended abdomen, severe hypotrophy, arm tremors, and right testicular retention. Anthropometric measurements revealed height (80 cm) and weight (8.0 kg) below the 3rd percentile, with a head circumference of 46 cm.
Genetic analysis via whole-exome sequencing (WES) identified a homozygous c.834dup p.(Arg279ThrfsTer5) mutation in the LARP7 gene (rs763920099), located on chromosome 4q25. This frameshift variant is predicted to cause premature truncation of the protein, impairing mRNA stability and translation, and ultimately leading to reduced protein synthesis—consistent with the pathophysiology of Alazami Syndrome.

Conclusion: This case highlights the clinical and genetic features of Alazami Syndrome and represents the first confirmed instance in an individual of Albanian descent. Early recognition and genetic diagnosis are crucial for clinical management and genetic counseling of affected families.

Keywords: Alazami syndrome; LARP7, Short stature, Intelectual disability.


Macedonian Society
for Rare Diseases


PEDIATRIC
ASSOCIATION OF
MACEDONIA
OUR CHILDREN'S SAFETY COMES FIRST


STOP
SMA


РЕТКО Е ДА СИ РЕДОК
RRALLË ËSHTË TË JESH I RRALLË
RARE IS TO BE RARE


LIFE
CHALLENGES
Life is a puzzle,
collect it.


МДАМ




EXCEED
ORPHAN


BIOMARIN


lek
a Sandoz company


Takeda


GENESIS
pharma


novo nordisk®


Amicus
a Swixx BioPharma company


MEDIS

10TH ANNIVERSARY MEETING OF RARE DISEASES IN SOUTH EASTERN EUROPE

ALPORT

& 3RD BALKAN ALPORT MEETING

HOTEL SILEKS
OHRID
NORTH MACEDONIA

2-4
OCTOBER

